

Circulation

JOURNAL OF THE AMERICAN HEART ASSOCIATION



Investigation of Chronic Venous Insufficiency : A Consensus Statement

A. N. Nicolaides

Circulation 2000;102:e126-e163

Circulation is published by the American Heart Association, 7272 Greenville Avenue, Dallas, TX 72514

Copyright © 2000 American Heart Association. All rights reserved. Print ISSN: 0009-7322. Online ISSN: 1524-4539

The online version of this article, along with updated information and services, is located on the World Wide Web at:

<http://circ.ahajournals.org/cgi/content/full/102/20/e126>

Subscriptions: Information about subscribing to *Circulation* is online at
<http://circ.ahajournals.org/subscriptions/>

Permissions: Permissions & Rights Desk, Lippincott Williams & Wilkins, a division of Wolters Kluwer Health, 351 West Camden Street, Baltimore, MD 21202-2436. Phone: 410-528-4050. Fax: 410-528-8550. E-mail:
journalpermissions@lww.com

Reprints: Information about reprints can be found online at
<http://www.lww.com/reprints>

Investigation of Chronic Venous Insufficiency A Consensus Statement

A.N. Nicolaides, MS, FRCS, FRCSE*

Abstract—This consensus document provides an up-to-date account of the various methods available for the investigation of chronic venous insufficiency of the lower limbs (CVI), with an outline of their history, usefulness, and limitations. CVI is characterized by symptoms or signs produced by venous hypertension as a result of structural or functional abnormalities of veins. The most frequent causes of CVI are primary abnormalities of the venous wall and the valves and secondary changes due to previous venous thrombosis that can lead to reflux, obstruction, or both. Because the history and clinical examination will not always indicate the nature and extent of the underlying abnormality (anatomic extent, pathology, and cause), a number of diagnostic investigations have been developed that can elucidate whether there is calf muscle pump dysfunction and determine the anatomic extent and severity of obstruction or reflux. The difficulty in deciding which investigations to use and how to interpret the results has stimulated the development of this consensus document. The aim of this document was to provide an account of these tests, with an outline of their usefulness and limitations and indications of which patients should be subjected to the tests and when and of what clinical decisions can be made. This document was written primarily for the clinician who would like to learn the latest approaches to the investigation of patients with CVI and the new applications that have emerged from recent research, as well as for the novice who is embarking on venous research. Care has been taken to indicate which methods have entered the clinical arena and which are mainly used for research. The foundation for this consensus document was laid by the faculty at a meeting held under the auspices of the American Venous Forum, the Cardiovascular Disease Educational and Research Trust, the European Society of Vascular Surgery, the International Angiology Scientific Activity Congress Organization, the International Union of Angiology, and the Union Internationale de Phlebologie at the Abbaye des Vaux de Cernay, France, on March 5 to 9, 1997. Subsequent input by co-opted faculty members and revisions in 1998 and 1999 have ensured a document that provides an up-to-date account of the various methods available for the investigation of CVI. (*Circulation*. 2000;102:e126–e163.)

Key Words: veins ■ valves ■ thrombosis ■ chronic venous insufficiency ■ tests

Chronic venous insufficiency of the lower limbs (CVI) is characterized by symptoms or signs produced by venous hypertension as a result of structural or functional abnormalities of veins. Symptoms may include aching, heaviness, leg-tiredness, cramps, itching, sensations of burning, swelling, the restless leg syndrome, dilatation or prominence of superficial veins, and skin changes. Signs may include telangiectasia, reticular or varicose veins, edema, and skin changes such as pigmentation, lipodermatosclerosis, eczema, and ulceration.

The most frequent causes of CVI are primary abnormalities of the venous wall and the valves and secondary changes due to previous venous thrombosis that can lead to reflux, obstruction, or both. Congenital malformations are rare causes of CVI. Because the history and clinical examination

will not always indicate the nature and extent of the underlying abnormality (anatomic extent, pathology, and cause), a number of diagnostic investigations have been developed that can elucidate whether there is calf muscle pump dysfunction and can determine the anatomic extent and functional severity of obstruction or reflux. The difficulty in deciding which investigations to use and how to interpret the results has stimulated the development of this consensus document. The aim of this document was to provide an account of these tests, with an outline of their usefulness and limitations and indications of which patients should be subjected to the tests and when and of what clinical decisions can be made.

The foundation for this consensus document was laid by the faculty at a meeting held under the auspices of the American Venous Forum (AVF), the Cardiovascular Disease

Received April 19, 2000; revision received July 13, 2000; accepted July 19, 2000.

From Irvine Laboratory for Cardiovascular Investigation and Research, Department of Vascular Surgery, Imperial College School of Medicine (St Mary's Campus), London W2 1NY, UK.

*See the appendix for a complete list of authors.

Correspondence to Prof A.N. Nicolaides, Irvine Laboratory for Cardiovascular Investigation and Research, Department of Vascular Surgery, Imperial College School of Medicine (St Mary's Campus), 10th Floor, Queen Elizabeth the Queen Mother Wing, Praed Street, London W2 1NY, UK. E-mail a.nicolaides@ic.ac.uk

© 2000 American Heart Association, Inc.

Circulation is available at <http://www.circulationaha.org>

Educational and Research Trust (CDER Trust), the European Society of Vascular Surgery (ESVS), the International Angiology Scientific Activity Congress Organization (IASACO), the International Union of Angiology (IUA), and the Union Internationale de Phlebologie (UIP) at the Abbaye des Vaux de Cernay, France, on March 5 to 9, 1997. Subsequent input by co-opted faculty members and revisions in 1998 and 1999 have ensured a document that provides an up-to-date account of the various methods available for investigating CVI.

Magnitude of the Problem

CVI has a considerable socioeconomic impact in Western countries due to its high prevalence, cost of investigations and treatment, and loss of working days.^{1,2} Varicose veins are present in 25% to 33% of female and 10% to 20% of male adults.³⁻¹³ In the Framingham study, the incidence of varicose veins per year was 2.6% in women and 1.9% in men.¹⁴ The prevalence of edema and skin changes such as hyperpigmentation and eczema due to CVI varies between 3.0%⁵ and 11%⁷ of the population.

Venous ulcers occur in \approx 0.3% of the adult population in Western countries.^{5,9,15-22} The prevalence of active and healed ulcers combined is \approx 1%.^{23,24} Healing of venous ulcers may be delayed in patients of low socioeconomic class, those who are single, and especially in those who do not have central heating.²⁵ The overall prognosis of venous leg ulcers is poor: only 50% heal at 4 months,²⁶ 20% remain open at 2 years, and 8% remain open at 5 years.²⁷ The annual recurrence rate varies from 6% to 15%.²⁸⁻³⁰ In 1 study, 12.5% of patients with ulcers took early retirement because of continued disability.³¹ Data from the Brazilian Security System show that CVI is the 14th most-frequently quoted disease for temporary work absenteeism and the 32nd most frequent cause of permanent disability and public financial assistance.³²

The annual cost of venous ulcers has been estimated to be £400 to 600 million for the United Kingdom^{33,34} and >\$1 billion for the United States.³⁵ The total cost of CVI to society, both direct and indirect, is estimated to be \$1 billion (US dollars) in each of 3 European countries (Germany, France, and the United Kingdom).^{36,37}

Pathophysiology of CVI

The symptoms and signs of CVI are produced by ambulatory venous hypertension, which is itself the result of obstruction, reflux, or a combination.

Changes in the Major Veins

Varicose veins are the most common manifestation of CVI. It is believed that they are usually due to abnormal distensibility of connective tissue in the vein wall. Early work has suggested that veins from patients with varicosities are more distensible than those from patients with normal veins,³⁸ indicating a probable systemic basis for the abnormality. Varicosities usually start at points where superficial veins communicate with deep veins, particularly at the saphenofemoral and saphenopopliteal junctions and in the perforating system, because of valvular incompetence. Primary varicose veins result from venous dilatation without previous

thrombosis. Secondary varicose veins are caused by valvular damage after deep vein thrombosis (DVT) and recanalization that gives rise to incompetent deep and perforating veins. Sometimes, varicose veins may be associated with reflux through vulvar varices without any relation to the saphenofemoral junction or other deep-to-superficial reflux in the lower limb. Such varices also may be associated with clinical symptoms and signs suggestive of pelvic congestion, including uterine retroversion and dyspareunia. They are more common in women who have had several pregnancies and had had hemorrhoids and vulvar varicosities during and after pregnancy.³⁹⁻⁴¹ Poor venous drainage and resulting venous hypertension increase transmural pressure in postcapillary vessels, producing skin capillary damage, fluid exudation, edema, and tissue malnutrition, which favors inflammation, infection, thrombosis, and tissue necrosis with lipodermatosclerosis and eventual ulceration.⁴²⁻⁴⁴

Reflux in deep veins can be due to past venous thrombosis and recanalization with destruction of venous valves, but it can also be idiopathic. Descending phlebography in limbs with deep venous reflux detected with duplex scanning fails to show any evidence of a previous DVT in \approx 30% of cases. In such limbs, reflux is the result of floppy valve cusps, valvular agenesis, or aplasia.⁴⁵⁻⁴⁷

Outflow obstruction can result from DVT without adequate subsequent recanalization and with poor development of collaterals. Less frequently, obstruction results from extramural venous compression^{48,49} or from congenital agenesis or hypoplasia of the femoral or iliac veins.⁵⁰ Left common iliac vein compression by the right common iliac artery is the most frequent type of external obstruction seen in young subjects.⁵¹⁻⁵⁴

Nearly 30% of fractures of the lower extremities result in venous thrombosis and postthrombotic sequelae.⁵⁵⁻⁵⁹ During military conflicts, severe injuries often involve major veins of the lower extremity. The long-term sequelae of postthrombotic changes become evident only many years after such injuries.^{60,61}

Venous recanalization occurs in 50% to 80% of patients several months or even years after DVT.⁶²⁻⁶⁹ Rapid recanalization after DVT is associated with a higher incidence of valve competency.⁶⁶ The chronic sequelae of DVT are most often ascribed to reflux rather than to obstruction.⁷⁰⁻⁷³

Several studies have investigated the relationship among acute DVT, long-term venous hemodynamic disturbances and the incidence of the postthrombotic syndrome.^{72,74-86} In these studies, the incidence of the postthrombotic syndrome was 35% to 69% at 3 years after DVT and 49% to 100% at 5 to 10 years, depending on the extent of the thrombosis. The incidence of the postthrombotic syndrome and the severity of the hemodynamic abnormalities increased when the popliteal or more proximal veins were involved in the original thrombotic episode. Patients with both chronic obstruction and reflux have the highest incidence of skin changes or ulceration.⁸⁶ Ulceration was more frequent in patients with recurrent DVT.⁸⁷ In recent studies in which patients with proximal thrombosis have been treated with adequate anticoagulation, early mobilization, and long-term prophylaxis with elastic compression, skin changes or ulceration were present in 4%

to 8% depending on the severity of the hemodynamic changes, duration of follow-up, use of effective compression therapy, local hygiene, and the cause.^{88,89}

Microcirculation: The Final Target of Venous Hypertension

New noninvasive techniques, such as laser Doppler,^{90,91} measurements of transcutaneous PO_2 ,⁹² and interstitial pressure,⁹³ capillaroscopy,⁹⁴ and microlymphography,⁹⁵ provide the means to study the extent of changes in the skin microcirculation of limbs with CVI.

The blood capillary circulation is often severely impaired in limbs with CVI,^{96,97} leading to skin changes, eczema, and ulceration. Changes in skin capillaries may be moderate in patients with mild venous insufficiency. The capillaries become markedly dilated, elongated, and tortuous, especially at skin sites with hyperpigmentation and lipodermatosclerosis, and in patients with insufficiency of the perforating veins or the deep venous system. These changes are associated with a high microvascular blood flow.^{98–102} As a late phenomenon, capillary thromboses successively lead to a reduction in nutritional skin capillaries and transcutaneous PO_2 , predisposing the patient to ulceration.^{94,103}

A striking finding in the skin of patients with CVI is a “halo” formation around the dilated capillaries observed on capillaroscopy. This is associated with microedema and pericapillary fibrin,¹⁰⁴ which possibly prevent normal nutrition to the skin cells as part of the final process in the development of venous leg ulcers.^{96,97}

Microangiopathy in lymphatics plays an important role (see Capillaroscopy) in the pathophysiology of skin changes and venous leg ulcers.^{105,106} Another finding is that white cells accumulate in legs with CVI on dependency.¹⁰⁷ Indirect evidence suggests that this finding could be the result of leukocyte activation^{108–110} and adhesion to the endothelium.^{111,112} The implications for the development of capillary loss and venous ulceration require further evaluation.¹¹³

Associated Hematological Changes

Since the late 1970s, many studies in patients with CVI have shown progressive changes in fibrinogen and associated blood properties, and impaired fibrinolysis.

Since the original observation of pericapillary fibrin deposits,¹⁰⁴ increased plasma fibrinogen levels have frequently been observed in patients with CVI.^{114,115} Elevated fibrinogen degradation products, particularly in patients with ulcers, indicate a rapid turnover of the macromolecule.¹¹⁶ Increased fibrinogen transport due to venous hypertension, high endothelial permeability, and plasma leakage found in such patients leads to significantly higher amounts of lymph fibrinogen than those found in normal subjects.¹¹⁷ Subsequent impaired fibrinolysis leads to hyperfibrinogenemia. Finally, although hyperfibrinogenemia can be related to aging and vascular risk factors, CVI is likely to play an independent role in the enhancement of the fibrinogen level.¹¹⁵

Elevated plasma fibrinogen levels are alleged to be the cause of rheological changes in viscosity and red cell aggregation.^{114,118–120} Whether fibrinogen-related red cell aggre-

gates in the microcirculation are an additional factor in the pathogenesis of CVI is not known.

Impaired fibrinolysis has been determined in several studies in all kinds of patients with varicosities^{121,122} and venous disease with and without skin lesions.^{123–125} The precise mechanism for the defect in fibrinolysis in the majority of patients appears to be an increase in the inhibitor plasminogen activator-1 (PAI-1) (“poor responders” type I).^{126–128} A defect in tissue plasminogen activator (“poor responders” type II) is infrequent.¹²⁷ PAI-1 is synthesized by the endothelium, particularly that of microvessels, and by smooth muscle cells of the microvessel walls. It is released by mechanical stress due to venous hypertension and by hypoxia. The maximum effect of this inhibitor occurs in lipodermatosclerosis, which favors the hypothesis of an important role for the affected microvessels in the skin. PAI-1 may therefore be considered a marker for damage to the skin microcirculation.^{126–128}

The rheological and fibrinolytic disorders are strongly correlated in CVI, particularly the PAI-1 levels and red cell aggregation. The red cell aggregation index is increased proportionally to the severity of the CVI.¹²⁷ Hyperfibrinogenemia, enhanced erythrocyte aggregation, and hypofibrinolysis may be interrelated factors, with their main effect being damage of the skin of the lower limbs. In patients with CVI, there is a risk of subsequent thrombosis in association with hypofibrinolysis when the PAI-1 levels become very high.¹²⁹

Other hematological alterations in CVI have not been fully explored. Abnormal levels of tissue factor can be detected in patients with CVI and functional tissue factor pathway inhibitor levels are decreased to create a thrombogenic state.¹³⁰ Soluble thrombomodulin levels are increased in CVI, suggesting endothelial dysfunction. The severity of CVI is also proportional to the inflammatory response.^{101,128,131,132} The tissue factor pathway inhibitor has anti-inflammatory properties. Initial investigations have shown upregulation of tissue factor, resulting in increased consumption of tissue factor pathway inhibitor.

In patients with long-term skin damage (lipodermatosclerosis), immunohistochemical studies have shown that capillaries of the papillary plexus in the skin are surrounded by an infiltrate of inflammatory cells (macrophages and T-lymphocytes), as well as the fibrin cuff.¹³³ The exact role of these cells is unclear, but they probably are important in the clinical changes seen in the skin.

Diagnostic Challenge

A careful clinical history and examination should reveal the patient’s symptoms, their severity, and whether they are due to venous disease rather than to coexisting nonvenous musculoskeletal, arterial, or neurological pathology. Subsequent noninvasive or, in some cases invasive, investigations may be required to confirm the clinical assessment.

The classic tourniquet tests provide some information about the sites of deep-to-superficial reflux, but they are difficult to interpret when varicose veins are not prominent and offer little information as to whether there is obstruction or reflux in the deep veins. They have been complemented by examination with hand-held continuous-wave Doppler; as a

result, it is now realized that many "recurrent" varicose veins are the result of unsuspected incompetent perforating veins or reflux in the short saphenous vein.

Because the history and clinical examination will not always indicate the nature and extent of the underlying abnormality (anatomic extent, pathology, and cause), a number of diagnostic investigations have been developed.¹³⁴⁻¹³⁶ Provided they are performed and interpreted by physicians or technologists who have a good knowledge of venous disease, they can provide qualitative and quantitative information and offer answers to most questions posed in clinical practice. They can be used to elucidate whether there is calf muscle pump dysfunction and determine the anatomic extent and severity of obstruction or reflux. The difficulty in deciding which investigations to use and how to interpret the results has stimulated the development of this consensus document. The aim of this document was to provide an account of these tests, with an outline of their usefulness and limitations and indications of which patients should be subjected to the tests and when and of what clinical decisions can be made.

Methods of Investigation

Tests That Provide Information on Morphology

Ascending Phlebography

Until recently, ascending phlebography has been the method of choice to demonstrate patency of the veins, define the anatomy, and help to distinguish between primary and secondary disease. A second role has been to detect incompetent perforating veins. It is still used as the "gold standard" to establish the accuracy of new investigations that determine the presence or absence of disease or its anatomic extent. However, the development of several noninvasive tests, particularly duplex scanning, now makes it unnecessary in most cases. Its current application is limited to cases in which duplex scanning is unavailable, inadequate, or equivocal.

The examination is performed by injecting contrast medium into a vein on the dorsum of the foot and directing it into the deep veins with an ankle tourniquet. The ascent of the contrast is slowed down by a second midthigh cuff or by having the patient in a semierect position with use of a tilting table. It is possible to demonstrate deep veins consistently from the muscular veins in the calf up to the inferior vena cava but not the internal iliac or profunda femoris veins.¹³⁷⁻¹⁴¹ Good visualization of iliac veins and the inferior vena cava may require a percutaneous injection of contrast into the femoral vein combined with the Valsalva maneuver.

The phlebographic criterion for the diagnosis of DVT established by DeWeese and Rogoff¹⁴² is the presence of well-defined filling defects in opacified veins demonstrated on ≥ 2 radiographs. This criterion is also valid for chronic obstruction. Nonvisualization of ≥ 1 calf veins is not considered diagnostic of thrombosis because frequently not all of these veins are visualized in normal limbs. Nonvisualization of a calf vein or a more proximal vein with good opacification of its proximal and distal parts in the presence of collateral vessels is evidence of thrombotic obstruction.

Loose thrombus appears as a cylindrical filling defect surrounded by a thin white line of contrast medium. Obliter-

ation of the white line indicates adherence to the vein wall. Use of the image intensifier to obtain several views just before and after a Valsalva maneuver helps to distinguish most artifacts from thrombosis. Fresh thrombus fills most of the venous lumen but is not adherent to the wall. Old thrombus with recanalization produces irregularity of the venous wall. Incompetent perforating veins can be identified by the flow of contrast medium from deep to superficial veins.

Although phlebography has been deemed the gold standard in the detection of the presence, site, and anatomic extent of chronic venous obstruction, it cannot provide a quantitative functional assessment of its severity or the adequacy of collateral veins.¹⁴³

Descending Phlebography

The aim of descending phlebography is to demonstrate reflux in either the superficial or deep veins and to determine the points of leakage from the pelvis to the lower limbs and from deep to superficial veins. It also is used to provide information on the anatomic localization and morphology of the venous valves, assess the extent of reflux, delineate the venous anatomy in complex cases, and differentiate primary from secondary disease. The criticism that descending phlebography is a nonphysiological test because it involves the use of contrast agents that are heavier than blood merits recognition, but this does not invalidate the observations that are gained from a careful study.

Descending phlebography can be performed by introducing a cannula through a brachial, contralateral, or ipsilateral femoral¹⁴⁴ or popliteal¹⁴⁵ vein and injecting contrast medium with the patient in the standing position with the use of a tilting table. A Valsalva maneuver is required to elicit valve closure. A popliteal injection is necessary if distal reflux is suspected in the presence of competent proximal valves. Repeated boluses of contrast medium are injected with serial or continuous recording. The competence of deep veins as well as the deep-to-superficial junctions is assessed by determining the extent and duration of distal reflux of contrast medium. Several variations in the technique of phlebography have been described.^{46,144-158}

Five grades of phlebographic reflux (0 to 4) have been described as follows^{151,153,154}: grade 0 indicates no reflux below the confluence of the superficial femoral and profunda femoris veins; grade 1, reflux into the superficial femoral vein but not below the middle of the thigh; grade 2, reflux into the superficial femoral vein but not through the popliteal vein, demonstrating competent popliteal valves; grade 3, reflux to a level just below the knee, indicating incompetent popliteal valves, but competent valves in the axial calf veins; and grade 4, reflux through the axial veins (femoral, popliteal, and calf) to the level of the ankle. Pathological reflux through the popliteal vein has been shown to be associated with symptoms, but the association is not clear cut.¹⁵³

The disadvantages of descending phlebography are that it is invasive and costly and has potential complications. The development of duplex scanning that can be used to detect the presence and anatomic extent of reflux has resulted in a decrease in the number of descending phlebograms. The latter

are now performed mainly when deep venous reconstruction is being considered or before redo surgery for varicose veins when duplex scanning is not conclusive.

Varicography

Varicography involves the direct injection of contrast medium through a butterfly cannula into the superficial vein under investigation. It is a simple and valuable technique that can supplement ascending phlebography. It has a particularly valuable clinical role, not so much in primary varicose veins but rather in the elucidation of the anatomic connections of recurrent varicose veins as a "road map" to guide the surgeon.¹⁵⁹ On the operating table, it facilitates the use of minimal incisions and precise surgery.^{160–162} It is also used to define abnormal drainage patterns in patients with venous malformations.⁵⁰

Per-uterine Phlebography

Per-uterine phlebography has been used to demonstrate veins in the broad ligaments, ovarian plexus, and ovarian veins in patients with a suspected pelvic congestion syndrome.¹⁶³ After injection directly into the fundus of the uterus, pressure over the iliac fossa shows contrast filling the contralateral ovarian vein.^{164–166}

Selective Ovarian and Internal Iliac Phlebography

Selective ovarian and internal iliac phlebography are used to investigate patients with leg varices that fill from vulvar veins and who are suspected to have incompetence of the ovarian veins with reflux into the vulvar veins via the internal iliac. In such patients, the finding of bilateral ovarian reflux is often associated with the pelvic congestion syndrome.¹⁶³

The ovarian veins are investigated with selective catheterization via the basilic, right femoral, or internal jugular veins.¹⁴¹ After the injection of contrast medium, reflux is demonstrated by tilting the table or by a Valsalva maneuver. Contrast from either ovarian vein fills large varices in both the broad ligaments of the uterus and then passes through the obturator and internal pudendal veins to fill varices in the thigh and even to extend down to the calf. Sometimes, injection into 1 ovarian vein can be seen to reflux down both legs. Contrast medium may be returned to the pelvic varices and ovarian vein by reversing the table tilt. During this investigation, the internal iliac veins may also be catheterized to assess this possible source of reflux.¹⁶⁷ The description of ultrasound windows to abdominal and pelvic veins has made duplex scanning an alternative investigation.¹⁶⁸

The complications of all types of phlebography are pain, contrast extravasation, deterioration of renal function, localized infection, idiosyncratic reactions, and venous thrombosis.¹⁶⁹ Pain is alleviated by administering an analgesic agent to the patient and slowly injecting the contrast medium. Minimal pain, tenderness, or swelling on the day after the phlebogram are rarely severe and clear within days. The incidence of phlebographically induced thrombosis is reduced by flushing the veins with heparinized saline at the end of the examination. Nonionic contrast media should be used to minimize these complications.¹⁷⁰

Duplex Scanning

Duplex scanning has been used since the early 1980s to diagnose DVT.^{171–174} Its use has now been extended to detect obstruction or reflux and to determine their anatomic extent in CVI.^{175–177} Color flow duplex imaging provides instant visualization of blood flow and its direction and has decreased examination time and improved its accuracy. It has become conventional to show cephalad flow as blue and distal flow as red.

A 4- to 7-MHz multifrequency transducer is used. The saphenofemoral junction is examined first with the patient standing, facing the examiner, and holding onto a frame, with most of the weight placed on the opposite limb. Holding onto a frame provides stability and prevents muscle contractions, which produce blood velocity artifacts.¹⁷⁷ An alternative method would be to examine the patient in the 15° reverse Trendelenburg position with the Valsalva maneuver to elicit reflux, specifically for the examination of thigh veins.¹⁷⁸ This method produces similar results to those achieved when a pneumatic cuff is placed below the level of interrogation and reflux is measured after rapid deflation with the patient in the standing position. The advantage of the Valsalva maneuver in the 15° reversed Trendelenburg position is that it provides comfort for both patient and examiner. The disadvantage is that the test is dependent on a cooperative patient who is able to perform the maneuver.

The probe is placed longitudinally over the groin so that the distended femoral vein, the long saphenous vein, and their junction can be identified. If there is any difficulty, one can start with a transverse image, identify the 2 veins, and then visualize them longitudinally.¹⁷⁷ Several features identify a normal vein; they include red cell aggregates shown as echogenic intraluminal structures that move slowly cephalad,^{179–181} movement of venous valve cusps phasic with respiration, smooth lining of the venous wall, and approximation of the anterior and posterior walls with compression. High echoes in the lumen, irregular walls, and failure to fully approximate the walls by compression indicate old thrombosis with or without recanalization.

Additional help in the elucidation of the anatomy and pathology is provided with color-flow duplex imaging. In normal veins, cephalad flow phasic with respiration is indicated by the blue color in the lumen. This is enhanced with distal thigh or calf compression. On release of the compression, reflux is shown as red that lasts for >0.5 second.^{182–184} In the absence of reflux, the lumen is black. In the presence of old thrombosis with recanalization, color-flow imaging shows blue among the luminal echoes on distal limb compression and red on release of the compression. The extent of venous changes can be determined by repeating these maneuvers throughout the length of the leg. If there is iliac occlusion, collateral circulation in the groin with suprapubic flow that crosses to the opposite groin can be visualized.

The short saphenous and popliteal veins are examined with the patient standing and facing away from the examiner and holding onto the frame. An alternative position is to sit on the edge of a couch with the foot on a chair or stool. In this position, both the popliteal and calf veins can be examined with comfort for both the patient and the examiner.¹⁷⁷ The

probe is placed over the popliteal fossa longitudinally to image the popliteal artery, which lies deepest; the popliteal vein lies more superficially and parallel to it; and the short saphenous vein is the most superficial. The main gastrocnemial veins (medial and lateral) are seen in the gastrocnemius muscle between the short saphenous and popliteal veins. The sites and levels of the junctions of these veins in relation to each other and the popliteal vein are identified. If an operation is contemplated, these levels can be marked on the skin. This is very helpful in view of the variable anatomy of the popliteal fossa.^{185,186} Features of normality, chronic obstruction with or without recanalization, or reflux are identical to those mentioned earlier.

The posterior tibial and peroneal veins can also be tested for reflux with anterolateral or posteromedial views.¹⁷⁷ They are usually paired, lying on each side of the corresponding artery. Cephalad flow or reflux can be identified with compression of the foot or lower calf followed by sudden release.

Incompetent perforating veins are identified by sliding the transducer up and down the leg with dilated superficial varicose veins imaged in transverse section. A perforating vein appears as a vessel that joins the superficial vein being examined with a deep vein. At this point, the probe is held still, the color flow is switched on, and distal compression is performed. The presence of 1 color (eg, blue) on compression with a different color on release (eg, red) indicates reflux. Reflux is diagnosed by outward flow that lasts >0.5 second. Although duplex scanning can localize incompetent perforating veins, there is considerable controversy as to whether it can be used to assess their hemodynamic significance.^{187–191}

Duplex scanning is operator dependent, and imaging can be difficult in certain circumstances, especially when operating above the inguinal ligament, in obese patients, and in those with swollen legs, in which case phlebography may be a better choice.^{192–194}

Recent Applications of Duplex Scanning: New Messages That Have Emerged

Duplex Scanning in the Study of the Natural History of Thrombi. Recent studies have shown that duplex scanning is an ideal method for serial examinations to monitor the evolution of thrombi and to check for the appearance of reflux after acute DVT.^{66–69,195,196} These studies indicate that reflux develops progressively and that even a complete occlusion may alternately partially recanalize and reocclude before a final complete recanalization. However, the factors that cause reflux to develop in some patients and not in others remain unclear.

The process and rate of organization of a thrombus may have the potential to identify those patients most at risk of developing late symptoms. Analysis of echogenicity of thrombi in vivo shows that the organizational process and rate of thrombolysis differ greatly from patient to patient.^{68,69} The resolution of thrombi follows 1 of 3 distinctive sequences: (1) rapid spontaneous thrombolysis, which preserves valvular function and returns the vein to its normal appearance; (2) increasing echogenicity, indicating fibrosis of a thrombus that remains occlusive, with or without evidence of collateral veins and with no symptoms at 1 year; and (3) slow recanalization that causes the destruction of valves, resulting in reflux and early postthrombotic symptoms.

Relationship Between Anatomic Extent of Reflux and Grade of Chronic Venous Disease. Duplex scanning is a very sensitive diagnostic method. It can show whether reflux is in the deep, superficial, or perforating veins or in any combination thereof. It can detect small amounts of reflux in isolated segments of veins often present in “normal” asymptomatic individuals. It can determine whether reflux is confined to a vein above or below the knee or whether it extends throughout the whole limb.

In the absence of deep venous obstruction, limbs with reflux confined to the proximal (above knee) veins rarely develop skin changes or ulceration.^{197,198} In contrast, even in the presence of normal deep veins, symptoms and signs of CVI are more often found when the entire length of the greater saphenous vein is involved or when reflux is present in both the long and short saphenous veins.^{197,198} Multisegmental reflux is significantly more prevalent in legs with ulcers than in nonulcerated limbs (75% versus 22%).¹⁹⁹ A pattern of reflux that involves ≥ 2 of the venous systems (superficial and deep; superficial and perforating; or superficial, perforating, and deep) is found in about two thirds of patients with skin changes or ulceration.^{198–202}

The available data suggest that there is a strong association between the severity of CVI and the anatomic distribution and extent of venous reflux.²⁰³ However, the information is fragmented in multiple studies that use different classifications and reporting methods. Therefore, further studies with uniform criteria that combine the anatomic information provided by duplex scanning and pressure or plethysmographic quantitative measurements are needed to establish such an association.

Significance of Gastrocnemial Reflux. The importance of gastrocnemial reflux was recognized by Dodd^{204,205} and May and Nissl⁶⁴ but has only recently obtained general recognition as a cause of primary venous insufficiency and, more important, as a common cause of recurrence.^{206–208}

When gastrocnemial vein incompetence is suspected, the demonstration of reflux by duplex scanning is mandatory because reflux can be eliminated by surgical ligation.^{206,209–211}

Liquid Crystal Thermography

Thermography immediately after a tiptoe exercise demonstrates incompetent perforating veins as “hot spots.”^{212–215} When compared with operative findings and phlebography, it has a sensitivity of 94% and 98%, respectively.^{216,217} The recent development of liquid crystal thermographic plates¹⁷⁴ has simplified the method, so it can be used as a screening test to localize incompetent perforators.²¹⁸ The liquid crystal thermographic plates are applied to the thigh and leg after 20 tiptoe movements. Incompetent perforating veins appear as clearly defined hot spots. Compared with duplex scanning, the positive predictive value of this test is 91%.²¹⁸ It appears that liquid crystal thermography is an accurate, simple, relatively inexpensive, and rapid method that allows preoperative marking of incompetent perforating veins without resorting to duplex scanning.

Tests That Provide Hemodynamic Information

Ambulatory Venous Pressure

Ambulatory venous pressure (AVP) measurements can supplement the anatomic information provided by phlebography.

TABLE 1. AVP P_{10} and Change in Pressure After 10 Tiptoe Movements in Different Groups of Patients

	Kriessmann, 1975 ²²⁷	Nachbur, 1971 ²²⁶	Nicolaides et al, 1993 ²³⁴	Partsch, 1978 ²²⁸	De Marees et al, 1978 ²²⁹
Normal					
P_{10}	...	24±1	15–30	...	24±11
P_0-P_{10}	58 ±10	54±6	...	66±9	44±7
Primary varicosis					
P_{10}	...	36±15	25–70	...	64±10
P_0-P_{10}	20 ±10	38±17	...	52±12	23±6
Postthrombotic syndrome					
P_{10}	...	69±19	25–85
P_0-P_{10}	7±6	36±5	...	18±9	...

Values are mean±SD or range and are given in mm Hg.

The test is based on the original observation made in the 1940s that the venous pressure in the foot decreases during walking²¹⁹ and gradually returns to the resting value when walking stops. It has been used extensively in Scandinavian countries to evaluate venous pathophysiology.^{220–224} In the 1970s and 1980s, AVP measurements became the hemodynamic gold standard used in the development of noninvasive methods for screening and diagnostic evaluation.^{225–230}

Venous pressure is measured by inserting a needle into a vein on the dorsum of the foot; the needle is then connected through a pressure transducer and an amplifier to a potentiometric pen recorder. It has been suggested that erroneous results may be obtained if there is a competent valve in the foot and that the needle may have to be replaced in the lower leg.²³¹ The patient supports himself of herself in the standing position by holding onto an orthopedic frame so the resting pressure is recorded. Holding the frame prevents contractions of the calf muscle, which may produce artifacts during the resting period before and immediately after exercise. The patient then performs a standard exercise of 10 tiptoe movements²³⁰ or knee bends²²⁷ at the rate of 1 per second, synchronous with a metronome. Walking on a treadmill is technically more difficult to perform but can be taken as a reference stress test. An alternative method with 10 manual compressions of the calf performed by the examiner has been shown to be more reproducible than the classical tiptoe method.^{178,232} At the end of the exercise, the patient remains still while recovery of the pressure to baseline level is recorded in seconds. The exercise is then repeated after either the inflation of a 2.5-cm-wide pneumatic cuff at the ankle or the use of digital compression to occlude the superficial

veins. The width of the cuff is critical because wider cuffs tend to compress deep as well as superficial veins. Likely sites of deep-to-superficial reflux may be determined by repeating the exercise with the cuff positioned just below the knee and at the lower and upper thigh.²³⁰ However, the use of tourniquets to attempt to occlude the superficial veins does not reliably differentiate between deep and superficial venous reflux.²³³

AVP is the best method to assess venous hypertension. The pressure at rest (P_0), the mean AVP during the steady state toward the end of the 10 tiptoe movements (P_{10}), the calculated difference of the 2 pressures (P_0-P_{10}) (Table 1), and the RT are the most useful measurements. Because of the exponential character of the refilling curve, it is much easier and more accurate to define the 50% ($t/2$) or the 90% RT than the 100% RT. Considerable variation has been found within normal groups as well as overlapping values between limbs with primary varicose veins or with the postthrombotic syndrome (Table 1). P_{10} is considered to be a measure of the severity of venous hypertension regardless of whether the latter results from obstruction or reflux in the superficial or deep venous systems or both.²³⁴ Values of P_{10} in different pathoanatomic states are shown in Table 2, the relationship of P_{10} with the prevalence of ulceration is shown in Table 3, and the range of values of 90% RT in limbs with different pathology identified with phlebography is shown in Table 4.

If there is severe outflow obstruction and extensive deep venous reflux, including reflux in the popliteal vein, P_{10} may actually become higher than P_0 because of the increased blood flow and venous volume due to exercise hyperemia. This is characteristic of a group of patients who complain of

TABLE 2. Values of AVP P_{10}

Type of Limbs	No Ankle Cuff	Ankle Cuff Inflated
Normal	15–30	15–30
Primary varicose veins and competent perforators	25–40	13–30
Varicose veins and incompetent perforators	40–70	25–60
Deep venous valve incompetence and proximal occlusion	55–85	50–80
Proximal occlusion and competent popliteal valves	25–60	10–60

Values are given in mm Hg (95% range).

From Nicolaides and Zukowski.²³⁰

TABLE 3. Prevalence of Leg Ulceration (Active or Healed) in Relation to AVP (P_{10}) in 251 Limbs

No. of Limbs	P_{10} , mm Hg	Prevalence of Ulceration, %
34	<30	0
44	31–40	12
51	41–50	22
45	51–60	38
34	61–70	57
28	71–80	68
15	>80	73

From Nicolaidis et al.²³⁴

“bursting” pain on walking (venous claudication). In another subgroup with outflow obstruction and competent popliteal valves, venous pressure in the foot may become normal during exercise because the valves protect the leg despite the proximal occlusion, although extremely high pressures may develop in the veins in the thigh.

Because AVP testing is invasive, it cannot be repeated frequently or used for screening. Noninvasive screening tests such as photoplethysmography (PPG), Doppler ultrasound, air-plethysmography, and foot volumetry are more frequently used for routine investigation. Nevertheless, AVP testing remains the gold standard for the assessment of overall hemodynamic function and for validation of noninvasive tests. As a research tool, it must be used to assess the hemodynamic effect of surgical reconstructive procedures in the deep veins to develop criteria for improved selection of patients.

An attempt was made to correlate AVP with the grades of reflux defined by descending phlebography in patients with skin changes or ulceration.²³⁵ If the popliteal valves were competent (grades 0 to 2), the range of AVP was 32 to 68 (mean 48) mm Hg, and an ankle tourniquet to eliminate superficial reflux resulted in an AVP of <45 mm Hg in all limbs. However, if the popliteal valves were incompetent (grades 3 and 4), the range of AVP was 50 to 95 (mean 72) mm Hg, and the application of an ankle tourniquet had little effect.

Femoral Vein Pressure Measurements

This method is used to determine the severity of ilio caval obstruction. A needle or catheter is inserted into the common femoral vein, and pressures are measured in the supine or semierect position at rest and after exercise. Exercise can be performed with 10 active dorsiflexions of the foot or 20 calf

TABLE 4. Values of Venous Pressure 90% Refilling Time

Type of Limb	No Ankle Cuff	Ankle Cuff Inflated
Normal	18–40	18–40
Primary varicose veins and competent perforators	10–18	18–35
Varicose veins and incompetent perforators	5–15	8–30
Deep venous valve incompetence	3–15	5–15

Values are given in seconds (95% range).

From Nicolaidis and Zukowski.²³⁰**TABLE 5. Arm/Foot Pressure Differential in Limbs With Outflow Obstruction**

Grade	Δp at Rest, mm Hg	Pressure Increment During Hyperemia, mm Hg
I: Fully compensated	<4	<6
II: Partially compensated	<4	>6
III: Partially decompensated	>4	>6 (often 10–15)
IV: Fully decompensated	>4 (often 15–26)	No further increase

From Raju and Fredericks.¹⁴³

muscle contractions. Elevated pressures after exercise are related to the severity of venous occlusion,²³⁶ but no set standards are available for femoral vein pressure parameters.^{237,238} Early investigations suggested that a pressure difference of 2 mm Hg between the femoral vein pressure and central venous pressure at rest and an increase of >3 mm Hg after exercise were associated with a significant proximal occlusion.²³⁹ A 3-fold increase in femoral vein pressure after exercise indicated an uncompensated proximal occlusion. More recently, a pressure difference of 5 mm Hg between the femoral and central venous pressures at rest in the supine position has been considered indicative of a significant proximal venous occlusion that requires surgical reconstruction.²⁴⁰

Arm/Foot Pressure Differential

The arm/foot pressure differential (Δp) provides hemodynamic information on the severity of obstruction and the adequacy of recanalization or of the collateral circulation.^{241,242} Venous pressures are recorded simultaneously in a vein of the foot and a vein in the hand, with the patient supine, and then repeated during reactive hyperemia or after the injection of papaverine.^{243,244} With these measurements, limbs with venous obstruction can be classified into 1 of 4 grades (Table 5). The more proximal the obstruction, the poorer is the compensation and the higher is the grade. The technique provides a global measurement of hemodynamic obstruction due to outflow occlusion in ≥ 1 vein. Venous obstruction involves >1 anatomic segment in 75% of limbs,¹⁴⁵ and additional direct femoral pressure measurements may be necessary for a more precise assessment of functional obstruction.

This method has the disadvantage of being invasive in that it requires 2 venipunctures. The technique has been compared with measurements of resistance and outflow fraction, with conflicting results in 2 studies.^{245,246}

In clinical practice, the main value of the method is to help select patients for venous reconstruction. A bypass procedure is not indicated unless a high arm/foot pressure differential (grade 3 or 4 obstruction) is present.²⁴¹

PPG, Light Reflection Rheography, and Quantitative Digital PPG

PPG and light reflection rheography are noninvasive techniques that can detect local changes in the blood content of tissues. The principal application is to study blood flow and blood volume changes in the skin.^{247–253} A probe that consists of a light source and a light-sensitive diode is positioned on the skin. Although skin is essentially opaque to light, slight light transmission and backscattering do occur in the range of

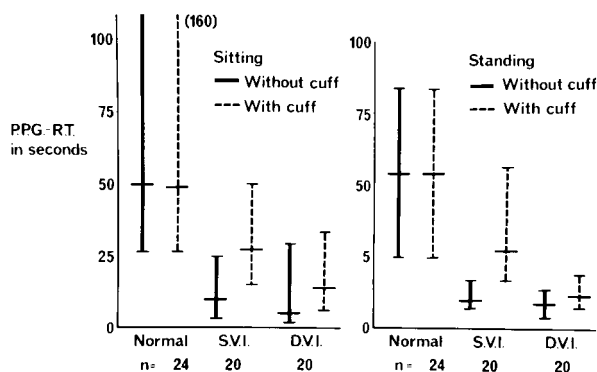


Figure 1. PPG-RT in normal limbs, limbs with superficial venous incompetence (SVI), and limbs with deep venous incompetence (DVI) in sitting and standing position (median and 90% range). Reproduced with permission from Nicolaides and Sumner.²⁴⁵

the visible and infrared light spectrum. The backscatter of light detected with the light-sensitive diode is affected by changes in the number of red blood cells in the dermis. Red blood cells absorb maximum light in the sitting or standing position when the pressure is high and the veins are full. Venous plexuses become less full and light absorption decreases as the venous pressure falls with exercise.

PPG Evaluation of Venous Reflux and Ejecting Capacity of the Calf Muscle Pump

In practice, the PPG probe can be fixed to the leg with transparent adhesive tape some centimeters proximal to the medial malleolus or to the dorsum of the foot. The PPG is set at zero once a resting baseline is achieved, and venous emptying is then produced through repeated dorsiflexion and plantar flexion of the foot. Most investigators perform this with the patient sitting on a couch with the legs vertical.^{247,254–258} Others prefer the standing position and tiptoeing 10 times to empty the veins.²⁵² When standing, it is essential for the patient to hold onto an orthopedic frame or table so artifacts from leg muscle contractions during the refilling period are avoided. When the test was performed in both the standing and sitting positions in the same patients, a better separation was obtained between patient groups when the patients were standing²⁵² (Figure 1).

In the 1980s, PPG had a limited application for quantitative measurements because of the inability to calibrate the signal and failure of the recorded signal to return to the same baseline. Only postexercise RT measurements were reproducible. A high degree of linear relationship was found for RTs measured with the simultaneous use of both PPG and venous pressure in 4 studies ($r=0.93, 0.96, 0.98,$ and $0.88,$ respectively),^{247,252,259,260} but this was not reproduced in a fifth study ($r=0.41$).²⁶¹

In practice, PPG is performed with a diagnostic algorithm shown in Figure 2 when valvular incompetence is suspected. If the venous RT (VRT) is abnormally short (<20 seconds in the sitting position²⁴⁷ or 25 seconds^{256–258} or 18 seconds in the standing position²⁵²), the test may be repeated after inflating a narrow (2.5 cm wide) cuff at the ankle or below the knee to occlude the superficial veins. Failure of the cuff to normalize the RT suggests deep venous or perforator incompetence. Normalization of the RT after occlusion of the

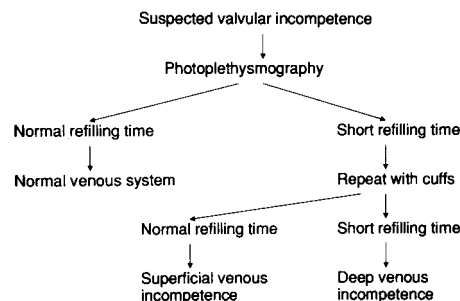


Figure 2. Relationship between PPG RT and mean AVP obtained in standing position (●, normal limbs; ▲, limbs with superficial venous incompetence; ○, limbs with deep venous incompetence). Reproduced with permission from Nicolaides and Sumner.²⁴⁵

superficial veins suggests that reflux is confined to the superficial venous system and that the deep veins have competent valves.^{245,252,258}

Although the PPG RT without and with occlusion of superficial veins can help to distinguish among limbs without major venous pathology, limbs with superficial venous incompetence, and limbs with deep venous incompetence, it is not considered to be a good indicator of the severity of deep venous insufficiency.^{262,263} Any AVP in the range of 45 to 100 mm Hg can be associated with a short RT of 2 to 10 seconds²⁵² (Figure 3) because RT depends on several factors, including the diameter of the vein in which the reflux occurs and the size of the reservoir to be filled. A long RT may be observed when reflux occurs in small-diameter veins despite a low volume reflux. In contrast, when reflux occurs in large-diameter veins in which the volume flow is large and the reservoir is filled rapidly, reflux can be very short. The PPG RT reflects regional rather than overall venous hemodynamics in the limb. It is related more to superficial than to deep venous insufficiency.²⁶⁴ An abnormally short RT in the absence of reflux in the main superficial trunks or deep veins on duplex examination suggests reflux through pelvic and vulvar veins.²⁶⁵ It is hardly surprising that PPG RTs correlate poorly with other methods.^{263,266}

PPG can be used for screening to detect CVI or to assess the overall physiological function of the lower limb veins

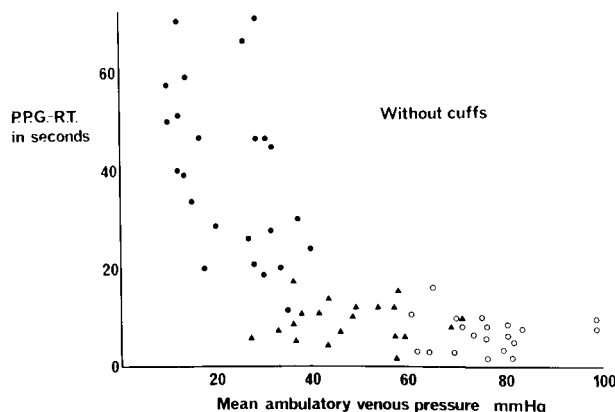


Figure 3. Algorithm showing that RT and its changes with application of cuffs to occlude superficial veins is a practical diagnostic tool. Reproduced with permission from Nicolaides and Sumner.²⁴⁵

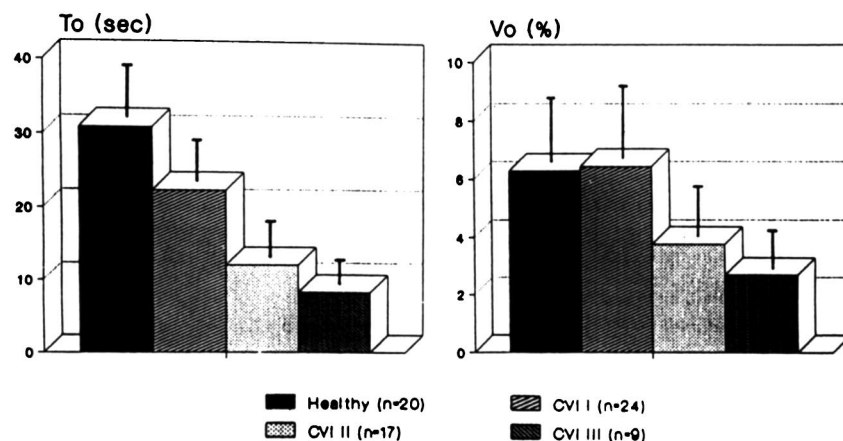


Figure 4. Mean To and Vo values in patients with CVI. Stage I indicates skin complications absent; stage II, skin complications present but no venous ulcer; and stage III, presence of history of venous ulcer. Reproduced with permission from Schultz-Ehrenburg and Blazek.²⁵⁶

without resorting to more invasive or expensive tests. Suspected reflux due to a short RT should always be confirmed with continuous-wave Doppler or, preferably, duplex scanning. The test should not be relied on to identify the anatomic distribution of disease.

Quantitative digital PPG^{255–258} is a more recent descendant of PPG. It incorporates modern computer technology with self-standardization and allows measurements of amplitude as well as time-related parameters. Recent studies have demonstrated that these measurements have a better quantitative relationship with symptoms than conventional PPG or light reflection rheography (Figure 4).²⁵⁶ Evaluations of muscle pump efficiency and venous long-term monitoring are also possible with the quantitative PPG.²⁵³

PPG Vein Occlusion Test: Evaluation of Venous Outflow Dynamics

The vein occlusion test measures VO during muscle rest. For the first time, it has become possible to measure VO rates with an optical sensor due to the calibration of the curve amplitude with quantitative PPG. The patient lies supine, with the extremity raised. The optical PPG sensor is attached to the inner or outer aspect of the lower leg. The entire measurement process is automatically conducted with quantitative digital PPG. Venous outflow is obstructed by means of a wide cuff (15 cm, 80 mm Hg) on the thigh for 2 minutes. In addition, a narrow cuff (2.5 cm, 80 mm Hg) is placed below the knee. The occlusion maneuver changes the optical properties of the skin by increasing the blood volume in the skin vessels, reflecting the changes in the total venous pool of the extremity. Among other parameters, venous capacity in PPG% and VO in PPG%/min can be determined from the resulting PPG curve. In the venous emptying phase, the outflow kinetics are measured over 30 seconds. VO gives the change in the PPG signal between 1 and 2 seconds after release of the occlusion. This change is >30%/min in healthy subjects.²⁵³ Although PPG is related more to superficial venous insufficiency, it is possible to assess deep VO dynamics when an additional narrow cuff is used, which forces the blood to make its way through the deep venous system. In the case of hemodynamically significant DVT or external tumor compression, the outflow value is reduced.²⁶⁷

Ambulatory Strain Gauge Plethysmography

Calf volume changes during exercise can be detected with strain gauge, and comparison with AVP measurements was

proposed by Holm et al in 1974.²⁶⁸ Originally, the strain gauge was applied at midcalf level, and the exercise consisted of 5 tiptoe movements; it was later changed to 10.²⁶⁹ Other researchers used walking on a treadmill²⁷⁰ or dorsiflexion of the foot in the sitting position²⁷¹ as exercise. Alteration in the mode of exercise to knee bends, the application of double strain gauges in plastic chains (Gutmann strain gauges), and recording at the supramalleolar region reduced the coefficient of variation for repeated measurements on the same day and for day-to-day variation from 40% to 12%.²⁷²

Ambulatory strain gauge plethysmography (ASGP) is used to measure calf volume changes in the upright position without the need to change position from the supine to the upright. This avoids the venoarteriolar reflex, which causes precapillary arteriolar vasoconstriction that may influence the venous return time.²⁷³ Strain gauges are applied to both ankles above the malleolus to avoid artifacts related to calf muscle contraction. Strain gauges are electrically calibrated in situ to percentage volume change (mL/100 mL). The preferred exercise is in the form of 20 knee bends (knee flexion 60°) at a rate of 30 per minute. After the exercise, the patient must stand completely still until full-volume restitution takes place, which in a normal person occurs between 1 and 2 minutes after cessation of the exercise. The plethysmographic recording allows calculation of venous refilling time (RT) and expelled volume (EV). The second part of the examination involves the application of a below knee compression cuff that is 2.5 cm wide and inflated to a pressure of 70 mm Hg. In patients with isolated superficial venous reflux, this compression will normalize the venous return time. Reference values for normal controls are RT of 42 to 96 seconds and EV of 0.7 to 3.1 mL/100 mL.

The reproducibility for ASGP was calculated with ANOVA.²⁷² For consecutive measurements, the coefficients of variation for RT were 4.7% in normal limbs and 8.8% in limbs with CVI. Corresponding values for EV were 11.3% and 13.1%. The coefficients for day-to-day variation were 7.8% for RT and 11.5% for EV. The positive predictive value for the presence of CVI was 100% for both RT and EV, and the negative predictive value for absence of chronic venous disease was 94% for RT and 75% for EV.²⁷⁴ Thus, ASGP is suitable for screening to exclude venous disease.

AVP is the gold standard to which external volumetric methods refer. The coefficient of correlation between AVP

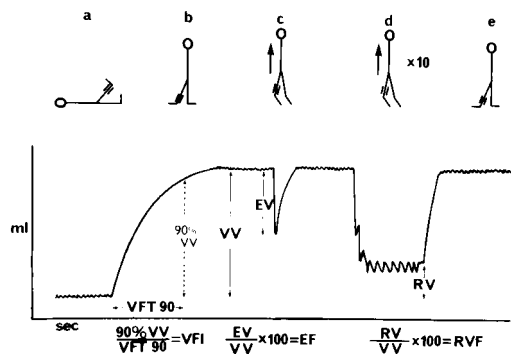


Figure 5. Diagrammatic representation of typical recording of volume changes during standard sequence of postural changes and exercise. a, Patient in supine position with leg elevated 45 degrees. b, Patient standing with weight on nonexamined leg. c, Single tiptoe movement. d, Ten tiptoe movements. e, Return to resting position as in b. Reproduced with permission from Nicolaides and Sumner.²⁴⁵

and ASGP was 0.91 ($P < 0.001$) for RT and 0.41 for EV ($P < 0.05$), respectively, as determined in 41 patients and 8 normal control patients.²⁷³ The poor correlation between EV and AVP may be explained by possible variations in venous and tissue compliance that determine the shape of the pressure-volume relation curve; in addition, small EV leg changes reflect a high percentage of blood volume changes.^{275,276}

ASGP is used to quantify the performance of the venous muscle pump in terms of venous reflux and expelled volume. It may differentiate superficial from deep venous insufficiency, but it cannot precisely localize the site and extent of the reflux or obstruction in either system. For this purpose, duplex scanning with color flow imaging is required.

Symptoms of CVI such as pain, itching, swollen legs, pigmentation, heavy legs, and objective changes in the skin have been shown to correlate with the ASGP-derived parameters for venous muscle pump function.²⁷⁴ The lowest values of RT and EV were recorded in patients with venous ulceration.²⁷⁴

ASGP may be used to screen for and to quantify CVI.²⁷³ It may also be used to evaluate venous claudication.²⁷⁷ It can be used to differentiate between CVI and lymphedema.²⁷⁸ Although duplex scanning is excellent for localization and diagnosis of venous reflux, ASGP provides quantitative information and is suited for the assessment of surgical outcome²⁷⁴ and that of compression therapy.²⁷⁸ In 1 study, ASGP allowed a longitudinal follow-up and could demonstrate that venous function

TABLE 6. Prevalence of the Sequelae of Venous Disease in Relation to VFI in 134 Limbs With Venous Disease Studied With Air-Plethysmography

VFI, mL/s	Chronic Swelling, %	Ulceration, %	Skin Changes, %
<3	0	0	0
3-5	12	0	19
5-10	46	46	61
>10	76	58	76

From Christopoulos et al.²⁸⁰

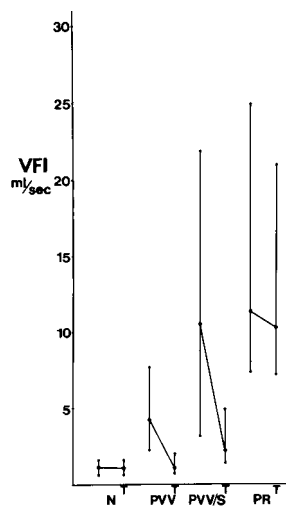


Figure 6. VFI (median and 90% range) without and with a tourniquet (T) that occluded superficial veins at knee in normal (N) limbs, limbs with primary varicose veins without sequelae of chronic venous disease (liposclerosis and ulceration) (PVV), limbs with primary varicose veins with sequelae of chronic venous disease (PVV/S), and limbs with popliteal reflux (PR). Reproduced with permission from Nicolaides and Sumner.²⁴⁵

had progressively deteriorated through pregnancy but had normalized 3 months after term.²⁷⁹

Air-Plethysmography

Venous hypertension is the result of impaired venous return. The latter is often due to the combined effects of venous reflux, obstruction, and poor calf muscle pump function. Air-plethysmography has the ability to measure each of these 3 components and, by doing so, has improved the understanding of venous pathophysiology.

The air-plethysmograph consists of a 35-cm-long polyurethane tubular air chamber that surrounds the entire leg. The air chamber is inflated with air at 6 mm Hg and connected to a pressure transducer/amplifier and a recorder or computer. A syringe connected to the air circuit is used for calibration. Changes in the volume of the leg as a result of filling or emptying of veins produce corresponding changes in the pressure of the air chamber. Thus, leg volume changes can be measured in milliliters according to the calibration.²⁸⁰

Evaluation of Venous Reflux

With the patient supine, the leg is elevated 45° with the knee slightly flexed to empty the veins. After a plateau is reached (Figure 5), the patient is asked to stand up with the knee of the examined leg slightly flexed and the weight on the opposite leg. An increase in leg volume is observed due to venous filling. The functional venous volume (VV) is 80 to 150 mL in normal limbs and up to 400 mL in limbs with CVI.^{280,281} The ratio of 90% of VV by the time taken for 90% filling (VFT90) is defined as the venous filling index

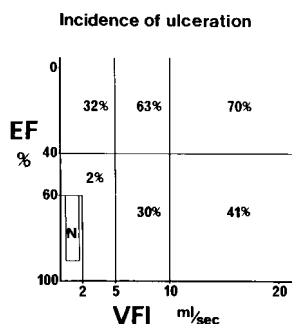


Figure 7. Incidence of leg ulceration in relation to VFI and EF of calf muscle pump in 175 limbs with venous problems. N indicates normal limbs. Reproduced with permission from Nicolaides and Sumner.²⁴⁵

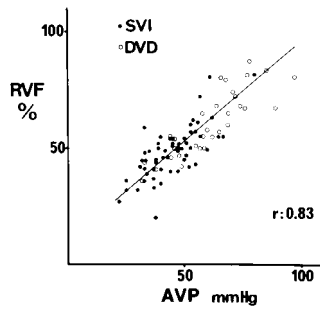


Figure 8. Relationship between RVF and AVP at end of 10 tiptoe movements (○, limbs with superficial venous incompetence; ●, limbs with deep venous disease). DVD indicates deep venous disease; SVI, superficial venous incompetence. Reproduced with permission from Nicolaides and Sumner.²⁴⁵

(VFI=90%VV/VFT90) (Figure 5). This is a measure of the average filling rate of the veins expressed in mL/s. The VFI is <2 mL/s in normal limbs in which the veins fill slowly from the arterial side. It may increase up to 30 mL/s in limbs with severe venous reflux.²⁸⁰ A VFI of >7 mL/min has a 73% sensitivity, a 100% specificity, and a 100% positive predictive value of identifying limbs with venous ulceration.²⁸² The prevalence of sequelae from CVI in relation to VFI is shown in Table 6. The prevalence of edema, skin changes, and ulceration increases with higher VFI regardless of whether the reflux is in the superficial or deep veins. When VFI measurements were repeated after surgery²⁸³ or after reflux in the superficial veins was abolished with finger compression of the long saphenous vein at the level of the knee, VFI was reduced to <5 mL/s in limbs with primary varicose veins but not in those with reflux in the deep veins (Figure 6). Reflux through the short saphenous vein is difficult to eliminate with finger compression.

Evaluation of the Ejecting Capacity of the Calf Muscle Pump

The patient is asked to do 1 tiptoe movement with the weight on both legs and to return to the initial position (Figure 5c). The recorded decrease represents the expelled volume (EV). The ejection fraction (EF) of the calf muscle pump is derived from the formula $EF = [(EV/VV) \times 100]$. EF is >60% in limbs without venous disease, 30% to 70% in limbs with primary varicose veins, and possibly as low as 10% in limbs with deep venous disease.²⁸⁰ The ejection capacity is as important as reflux for the development of venous ulceration. A good EF (>60%) was associated with a low incidence of ulceration despite marked reflux, and a poor EF (<40%) was found with ulceration in limbs with minimal reflux.²⁸¹ The EF and VFI measurements when used in combination have a good correlation with the incidence of ulceration and offer the potential

TABLE 7. Prevalence of Leg Ulceration in Relation to RVF in 175 Limbs With Venous Disease

No. of Limbs	RVF, %	Incidence of Ulceration, %
20	<30	0
24	31–40	8
48	41–50	18
43	51–60	42
32	61–80	72
8	>80	88

From Christopoulos et al.²⁸⁴

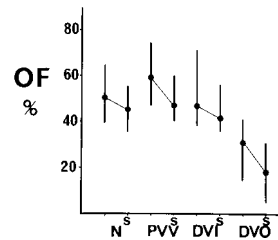


Figure 9. Outflow fraction (OF) (median and 90% range) without and with occlusion of superficial veins (s) in limbs of 50 normal volunteers (N), 157 limbs with primary varicose veins (PVV), 70 limbs with deep venous incompetence (DVI), and 68 limbs with venographic evidence of deep venous obstruction (DVO). Reproduced with permission from Nicolaides and Sumner.²⁴⁵

for the selection of patients most likely to benefit from deep vein reconstruction (Figure 7) (see later). They also offer a means of hemodynamic follow-up in natural history studies.

Overall Performance of the Calf Muscle Pump

The combined effect of venous reflux, obstruction, and ejection capacity is evaluated by measuring residual volume (RV) and residual volume fraction [$RVF = (RV/VV) \times 100$] after 10 tiptoe movements (Figure 5d). The RVF is in the range of 5% to 35% in normal limbs, 20% to 70% in limbs with primary varicose veins, and up to 100% in deep venous disease. It has a linear relationship with measurements of AVP (Figure 8) and the incidence of ulceration (Table 7).^{280,284,285}

Evaluation of Venous Outflow

Venous outflow is evaluated with use of the venous occlusion technique with the patient supine.^{286–288} A thigh tourniquet (10 to 12 cm wide) is placed as proximally as possible and inflated to 80 mm Hg. Volume increases to a new plateau. The tourniquet is then deflated suddenly, and the VO curve is recorded. The outflow fraction at 1 second (OF_1) is the VO expressed as a percentage of the total venous volume. The procedure is repeated after occlusion of the long saphenous vein at the knee. Figure 9 shows the measurements of OF_1 in limbs with and without venous obstruction according to phlebography, and Figure 10 shows the relationship between the OF_1 and measurements of the arm/foot pressure differential.²⁴¹ In clinical practice, an OF_1 of >38% is considered indicative of the absence of any functional obstruction; a range of 30% to 38% indicates moderate obstruction; and <28% indicates severe obstruction.^{245,287,288}

Measurement of Resistance

Venous outflow resistance can be calculated from the outflow curves for volume and pressure obtained simultaneously. Pressure is measured by inserting a 21-gauge butterfly needle into a vein in the foot and volume by placing the airplethysmograph around the leg. The foot is elevated 15 cm from the horizontal. A thigh cuff is inflated to 80 mm Hg for 2 minutes and then deflated suddenly (Figure 11). Flow (Q)

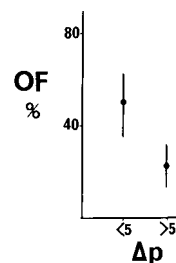


Figure 10. Outflow fraction (OF) (median and 90% range) in 15 limbs with deep venous reflux but no obstruction (arm/foot pressure differential $\Delta p < 5$ mm Hg) and 8 limbs with venographic deep venous obstruction ($\Delta p > 5$ mm Hg). Reproduced with permission from Nicolaides and Sumner.²⁴⁵

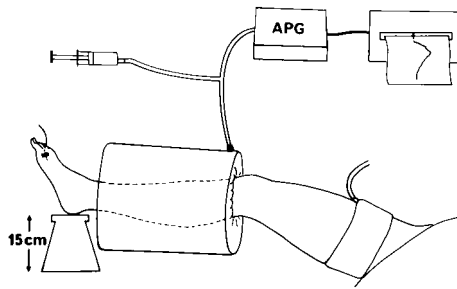


Figure 11. Position of leg and air chamber of plethysmograph (APG) for recording pressure and volume changes shown in Figure 12. Reproduced with permission from Nicolaides and Sumner.²⁴⁵

can be calculated at any point on the volume outflow curve from the tangent at that point (Figure 12). Resistance (R) is calculated as $R=P/Q$ at any time. The units are expressed in $\text{mm Hg} \cdot \text{mL}^{-1} \cdot \text{min}^{-1}$. By calculating resistance at several points along the outflow curve and plotting it against pressure, it is possible to demonstrate how resistance changes with different pressures. By measuring the outflow resistance in a large number of patients without and with various grades of obstruction (Raju test grades I to IV), the relationship between the resistance and grades of obstruction has been determined (Figure 13). The resistance/pressure relationship is not linear. The resistance is relatively low at high pressure, when the veins and collateral channels are distended. It increases as the pressure decreases and the veins “collapse.” The measurement of resistance is a new research tool that can be used in natural history studies of chronic venous obstruction.

The reproducibility of the air-plethysmographic measurements is shown in Table 8.

Recent Applications of Air-Plethysmography: New Messages That Have Emerged

In contrast to duplex scanning, which detects abnormalities in individual veins, air-plethysmography provides information derived from the entire leg. In contrast to segmental devices, because the air chamber includes all the muscles from ankle to knee, it avoids errors due to muscle movements during exercise. Although it can be used as a simple screening test, it has the potential of offering a complete analysis of venous

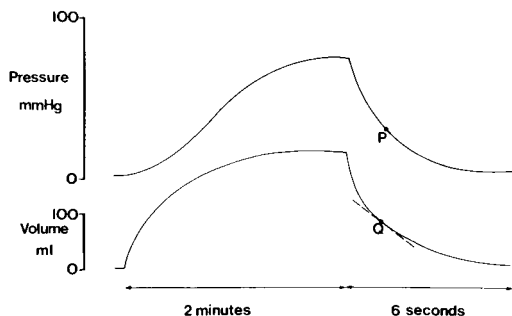


Figure 12. Pressure and volume venous occlusion inflow and outflow curves recorded simultaneously in same leg. Pressure is recorded with a needle in a foot vein, and volume is recorded with air plethysmograph. Reproduced with permission from Nicolaides and Sumner.²⁴⁵

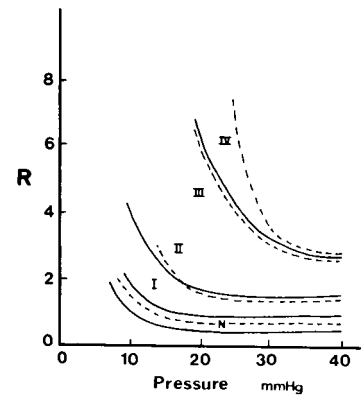


Figure 13. Relationship between outflow resistance curves and Raju's classification of grade I to IV outflow obstruction. N indicates normal limbs; R, resistance in resistance units. Reproduced with permission from Nicolaides and Sumner.²⁴⁵

hemodynamics. Thus, it is useful for routine clinical practice as well as for research.

Limbs with edema or ulceration due to causes other than venous, such as arterial, lymphatic, cardiac, or rheumatoid disease, can be distinguished from those affected by venous disease. In limbs with prominent varicosities, air-plethysmography can determine whether the latter act as collateral outflow channels.^{286,288}

Venous hypertension usually results from the combined effect of reflux, obstruction, and poor ejection. With air-plethysmography, the contribution of each parameter can be measured so the appropriate intervention can be considered. Surgical abolition of venous reflux in the deep or superficial system has already been shown to normalize venous hemodynamics in properly selected patients with no obstruction and unimpaired calf muscle ejection.^{283,290–295} The air chamber can be applied over an elastic stocking so the hemodynamic effect of the latter can be demonstrated.^{280,296–299} The method should be used in future studies to assess different kinds of compression.

Absolute volume measurements are dependent on the size of the limbs studied; ideally, these values should be normalized for the mass of tissue involved in the measurements.²⁸⁰ The most important values, however, are the ratios EF and RVF, which are already normalized.

TABLE 8. Reproducibility of Air-Plethysmographic Measurements (1 Normal Limb, 3 Limbs With Primary Varicose Veins, and 1 Limb with Deep Venous Disease Studied on 5 Different Days)

Measurement	Coefficient of Variation, %	
	Christopoulos et al, 1987 ¹³⁶	Yang et al, 1997 ²⁸⁹
VV, mL	10.8–12.5	7.0
VFT90, s	8.0–11.5	8.9
EV, mL	6.7–9.4	10.3
RV, mL	6.2–12.0	8.1
VFI, mL/s	5.3–7.9	13.4
EF, %	2.9–9.7	10.7
RVF, %	4.3–8.2	9.5

From Christopoulos et al¹³⁶ and Yang et al.²⁸⁹

TABLE 9. Foot Volumetric Measurements With Error of Determination

Variable	Unit	Error, %
Foot volume (v)	mL	1.1
Expelled volume (EV)	mL	4.3
Expelled volume per 100 mL tissue (EVR)	mL/100 mL	(9.8)
Refilling flow (Q)	mL · 100 mL ⁻¹ · min ⁻¹	32.3
Half refilling time (t/2)	seconds	16.2 (25.7)

Abbreviations are given in parentheses.

From Norgren et al³⁰⁷ and Partsch.²²⁸

Even in limbs with phlebographic evidence of DVT in the past, skin damage is rarely seen unless reflux is present.^{85,86,201,300} Air-plethysmography has been used to demonstrate that the venous volume, VFI (amount of reflux), and residual volume fraction worsen with increasing clinical severity.^{203,284,300–302} Overall, it appears that the severity of reflux is strongly associated with the grade of disease.

Usually, the skin around venous ulcers is warm and hyperemic, and occasionally pulsation can be detected with Doppler ultrasound. To explain this, several authors postulated the presence of arteriovenous shunts or reduced capillary resistance.^{303,304} The introduction of air-plethysmography in the 1980s provided a method of measuring the arterial inflow into the entire leg in milliliters per minute. Arterial inflow was measured with the venous occlusion technique in 25 normal limbs and 126 limbs with different grades of venous disease. Resting arterial inflow was 60 to 95 mL/min in normal limbs; 60 to 110 mL/min in 45 limbs with uncomplicated varicose veins; 65 to 162 mL/min in limbs with swelling, lipodermatosclerosis, or pigmentation; and 120 to 235 mL/min in limbs with ulcers.²⁹⁹ These results support the evidence from work with other methods such as laser Doppler that not only is there hyperemia in limbs with CVI but also this hyperemia increases with the severity of the clinical grade.

Foot Volumetry

Dynamic foot volumetry was developed in the early 1970s.^{305,306} It is based on the water plethysmographic principle and provides measurement of volume changes of the foot during exercise.

The foot volumeter consists of an open, water-filled box. The water level, which is initially 14 cm high, is sensed with a critically dampened photoelectric float sensor, of which the output is monitored on a strip-chart recorder. During a series of knee bends (usually 20) performed at the rate of 1 every 2 seconds, the blood volume gradually decreases until it reaches a steady state. After the exercise is completed, the blood volume returns to its preexercise level. The refilling rate depends on the arterial inflow and amount of venous reflux, if any. To differentiate between superficial and deep venous insufficiency, the exercise is repeated after tourniquet compression of the superficial veins, initially below the knee and then at the ankle just above the volumeter. The various measurements that can be made are listed in Table 9; the most important are the expelled volume (EV), the expelled volume rate (EVR), the refilling flow (Q), the ratio Q/EVR, and the half-refilling time (t/2). The ratio Q/EVR is a useful criterion for discrimination between healthy individuals and patients with CVI. Table 10 depicts normal values from 3 different studies.

The EV has been correlated with venous pressure during exercise ($r=0.66$ in controls; $r=0.70$ in a mixed patient population; $r=0.72$ with tourniquet compression of the superficial veins) and with phlebographic as well as clinical findings.^{307–309}

Foot volumetry can quantify the degree of venous insufficiency and indicate its location (superficial, deep, or both).^{307,310,311} It can be used to evaluate therapeutic interventions and to follow patients after DVT to determine the extent of valve damage.^{250,308}

The advantages of foot volumetry are that it can be used to assess the most distal parts of the leg (ie, those most affected by hydrostatic pressure) and that the local temperature is standardized. The use of knee bending demands mobility of the ankles. Contractures of the ankle joints reduce the movements and thereby also the expelled venous volume during exercise.³¹² Recently, a computerized version of foot volumetry was developed, which simplified the calculation of EV and Q. Foot volumetry has been used to study the effects of various treatments, such as surgery for varicose veins,^{250,313} compression treatment,^{314,315} venotonic drugs,³¹⁶ and treatment of DVT.^{78,82,236,317–322} Venous function during pregnancy has also been studied.^{323–325} It must be stressed

TABLE 10. Normal Values for Volumetric Parameters From 3 Different Studies

Variable	Norgren et al, 1974 ³⁰⁷	Partsch, 1978 ²²⁸	Lawrence and Kakkar, 1979 ³⁰⁸
n	29	17	36
Age, y	31 (20–50)	68 (62–75)	35.4
EV	17.0±7.5	8.8±3.7	18.3±6.8
EV per 100 mL tissue	1.5±0.5	0.8±0.3	1.4±0.4
Q	2.3±1.1	2.1±0.7	2.2±1.0
Q/EV per 100 mL tissue	1.6±0.8	2.8±1.2	1.5±0.6
Half refilling time (t/2)	25.9±12.0	13.2±5.0	26.4±10.2
Refilling time (t ₄)	101.2±38.8	...	86.9±34.3

Values are mean (range) or mean±SD.

that like any plethysmographic method, foot volumetry provides a global indication of calf pump function and reflux.

Continuous-Wave Doppler Ultrasound

Continuous-wave Doppler ultrasound is a useful method of detecting reflux at the saphenofemoral and saphenopopliteal junctions.^{326–331} It has become routine in outpatient clinics for screening because it is quick, inexpensive, and noninvasive. Expectations that it would be useful for detecting and localizing incompetent thigh and calf perforating veins were proved false by several studies in the 1970s.^{332–334}

The saphenofemoral junction is examined with the patient standing facing the examiner while holding onto a rail or table to ensure complete immobility and to avoid muscular contractions in the leg. The probe of a continuous-wave Doppler ultrasonic blood velocity detector (5 to 10 MHz) is placed over the common femoral vein at a 45° angle to the horizontal. The common femoral vein is found just medial to the artery. Confirmation that the probe is correctly positioned is obtained by a marked increase in the blood velocity signal after manual compression of the thigh or calf. The position of the probe is adjusted during repeated calf compression to obtain the optimum signal, ensuring that the ultrasonic beam is at the same plane as the axial stream. The patient is then asked to cough and to perform a Valsalva maneuver. Subsequently, the thigh or calf is compressed manually, producing a further augmented signal of flow toward the heart, and the compression is released suddenly. The absence of a detectable signal during the cough and Valsalva maneuver and on sudden release of thigh or calf compression means that there is no reflux. In contrast, a signal that lasts >0.5 second (usually 1 to 4 seconds) indicates reflux.^{329,332–335} In the presence of reflux, the thigh or calf is again compressed, and the compression is suddenly released while the long saphenous vein is occluded manually or with rubber tubing placed around the thigh below the saphenofemoral junction. Abolition of reflux means that the previously detected reflux is the result of an incompetent saphenofemoral junction. Persistence of reflux despite compression of the long saphenous vein indicates that it may be in the femoral vein. A duplex scan is often necessary to confirm reflux in the deep veins. In the presence of competent popliteal valves (see later), reflux in the superficial femoral is often associated with incompetent thigh perforating veins.

The saphenopopliteal junction is examined with the patient standing, facing away from the examiner and holding onto a railing or table. The weight of the body is taken mainly on the opposite limb. The knee on the side to be examined is flexed slightly with the heel on the ground and the foot slightly forward so as to relax the calf muscles. The Doppler probe is positioned at the level of the skin crease behind the knee to obtain signals from the popliteal artery and popliteal vein. The venous signal is augmented by calf compression, and fine adjustment of the probe position ensures an optimum signal. The calf is then compressed manually to detect venous flow toward the heart. If there is no retrograde flow after the sudden release of calf compression, then there is no reflux, indicating the presence of competent valves. If there is flow distally after the compression is released, then there is reflux

in either the short saphenous or popliteal veins. If there is reflux, then calf compression with sudden release is repeated with an assistant compressing the short saphenous vein just distal to the probe. If reflux persists despite digital compression of the short saphenous vein, it is inferred that the reflux is in the popliteal or gastrocnemius veins. Popliteal vein reflux can be detected by this method with a sensitivity of 100% and a specificity of 92% (ie, a false-positive rate of 8%).³²⁹ False-positive results are due to variations in the anatomy of the short saphenous vein and reflux in veins other than the popliteal.¹⁶¹

A limitation of continuous-wave Doppler ultrasound is that it cannot insonate an individual vessel because it detects flow in any artery or vein in the path of the ultrasound beam. At the level of the groin, reflux can be present in the long saphenous vein, its tributaries, or the common femoral vein. Doppler ultrasound cannot identify the exact site of reflux, and the findings should be confirmed with duplex scanning if surgery is contemplated.¹⁸⁵ Continuous-wave Doppler cannot be used to detect the level of the saphenopopliteal junction.³³⁵ Reflux in the gastrocnemius or the Giacomini vein can give false-positive results, indicating deep venous reflux despite the presence of competent popliteal valves. For this reason, the finding of venous reflux in the popliteal fossa must be followed with duplex scanning if surgery is contemplated.

Duplex Scanning (Quantification of Reflux)

Duplex ultrasound techniques detect reflux in individual veins, whereas plethysmographic methods measure reflux in the entire leg. To date, it appears that plethysmographic measurements have an advantage because they provide evaluation of the severity of reflux. Duplex examination is performed with the patient standing.¹⁷⁷ Reflux is elicited by manual or by pneumatic cuff compression of the calf with subsequent sudden release or rapid deflation. Three methods have been used in an attempt to evaluate the severity of reflux.

Rate of Reflux in at Peak Velocity

The rate of reflux (in mL/min) is calculated with the assumption that the veins are circular, so the cross-sectional area is calculated from the measured vein diameter. The reflux volume at peak reflux is calculated by multiplying the cross-sectional area by the mean peak velocity at the time of maximum reflux.^{336,337}

Reflux Time

The valve closure time is the time taken for the valve to close after compression is released. Duplex scanning shows that the normal valvular closure time in the standing position is <0.5 second,¹⁸² and reflux is considered to be present if the duration is longer. In limbs with multiple sites of reflux, individual valve closure times in the different vein segments have been added to produce the total valvular closure time, which has been reported as the total reflux time.^{199,266,337–342}

Reflux Index

The reflux index is a modification of the valve closure time method. The ratio of backward to forward velocity (area under the curve) is calculated.^{343,344} It has been suggested that with the use of this method during exercise or postocclusive

reactive hyperemia, it is possible to detect veins with inherent valvular weakness.

The severity of reflux quantified with duplex scanning with these techniques has shown a weak correlation with the plethysmographic quantification of reflux.^{262,345} This may be because there frequently are complex patterns of reflux in different vein segments. It would be very complicated and laborious to arrive at an estimation of total reflux by adding reflux in superficial, perforator, muscular, and deep veins. In addition, in patients with primary varicose veins who are examined in the standing position, calf compression produces mainly cephalad flow in the deep veins, whereas on release of the compression, reflux is confined to the superficial veins. In the presence of reflux in both the superficial and deep veins, the ratio of cephalad flow in the superficial veins to that in the deep veins during calf compression may be different than that during reflux.

Quantification of reflux in individual veins with duplex scanning is not required in routine clinical practice. It is a research tool.

Venous Tone (Pressure-Volume Relationship)

The volume of blood contained within a segment of vein is a function of the transmural pressure (P_{TM}), the mechanical properties (elasticity) of the venous wall, and the contractile state (tone) of smooth muscles within the media. Transmural pressure is the difference between the intravascular pressure in expansion of the vein and the pressure in the surrounding tissues in compression of the vein. In normal limbs, interstitial fluid pressures are usually subatmospheric (mean -2.5 mm Hg, range -5 to 1 mm Hg).³⁴⁶

Venous volume compliance (C_v) can be defined as the ratio of change in venous volume (ΔV) to the change in transmural pressure (ΔP_{TM}): $C_v = \Delta V / \Delta P_{TM}$. The venous pressure-volume curve is S shaped. At subatmospheric transmural pressures when the outside pressure exceeds that of the blood on the inside and at high transmural pressure, venous compliance is low and little change in volume occurs in response to a relatively large change in transmural pressure. Between these 2 extremes, veins are very compliant, because large changes in venous volume occur in response to relatively small changes in venous pressures.³⁴⁷

Venous tone is minimal under normal resting conditions and is largely controlled by sympathetic α -adrenergic activity.³⁴⁸⁻³⁵⁰ When veins are filled sufficiently to produce a roughly circular cross section, the contraction of smooth muscle within the vessel wall has an important effect on venous volume.³⁵¹ Peripheral veins have thicker walls with a higher smooth muscle content and constrict more intensely to sympathetic stimuli than do more centrally located veins. In general, veins contract in response to stimuli that increase cardiac output.³⁵² Both direct cold exposure and increased sympathetic activity mediated by a reduced core temperature cause venous constriction.³⁵³ Warmth dilates cutaneous veins both directly by relaxing vascular smooth muscle and indirectly by decreasing sympathetic activity.

Methods of measuring compliance and venous tone depend on the simultaneous determination of transmural pressure and venous volume. Absolute venous volume cannot be measured

directly, but changes in limb volume can be determined with air, water, or strain-gauge plethysmography. These changes are expressed as mL or mL/100 mL of tissue enclosed in the plethysmograph. A disadvantage with plethysmographic methods is that they do not differentiate between volume changes in superficial and deep veins. Diameter changes in individual larger veins can be measured with B-mode scans.^{354,355}

Because the measurement of tissue pressure is impractical, transmural pressure is estimated from the intraluminal venous pressure. Ideally, pressures are measured electronically through a catheter connected to a transducer with the catheter tip placed in the venous segment enclosed in the plethysmograph.³⁵⁶ Alternatively, pressures may be measured in a readily accessible superficial vein distal to the site of the plethysmograph. This provides a reasonably accurate estimation of venous pressure in a supine individual, but corrections must be made to accommodate the change in hydrostatic pressure in standing subjects or whenever there is a vertical disparity in the location of the plethysmograph and catheter tip. Another method is to calculate venous pressure from the length of the hydrostatic column from the site of volume measurement to the right atrium.³⁴⁸ This ignores the dynamic venous pressure produced by contraction of the left ventricle, but the error is relatively small (5 to 15 mm Hg). A third way of estimating venous pressure is to place a pneumatic cuff on the proximal part of the limb. The cuff is inflated to a pressure less than the arterial pressure, and venous pressure is assumed to approximate cuff pressure when the plethysmographic tracing reaches a plateau.

Because venous compliance varies with the degree of venous distention, measurements are best made by plotting a pressure-volume curve over the physiological range of venous pressures. This can be accomplished by rapidly increasing and decreasing venous pressure with a proximal occluding cuff. Even then, the resulting curves describe a hysteresis loop, so the compliance as pressure increases differs from that as it decreases^{357,358} (Figure 14). Due to viscous creep in the vein wall, these disparities are more pronounced when venous pressure is increased or decreased in increments, allowing the venous volume to stabilize at each succeeding pressure level.³⁵⁹ Moreover, at higher venous pressures, there is a slow loss of fluid through the capillary walls into the tissue spaces that causes a gradual increase in limb volume that is unrelated to venous elasticity. Tilting the patient to vary hydrostatic pressure is subject to the same errors.³⁴⁸

The measurement of venous compliance is not needed in routine clinical practice. It is a research tool that is helpful in elucidation of the pathophysiology of chronic venous disease and in assessment of the efficacy of therapeutic measures as indicated later.

Clinical Significance and Potential Applications of Measurements of Venous Tone

Venous compliance is crucial to our understanding of CVI and the venous pump mechanism.^{359,360} Venous compliance determines postural changes in limb volume, the rate of venous refilling, the shape and rapidity of VO during venous

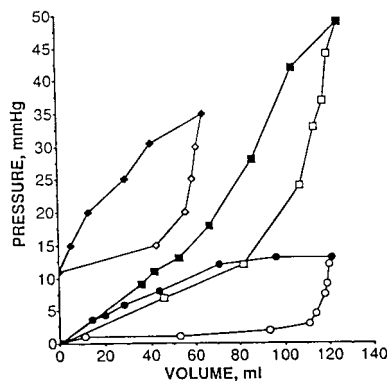


Figure 14. Typical filling and outflow pressure-volume loops during venous occlusion in 3 individual legs. Each loop is traced counterclockwise and consists of inflow curve (\diamond , \square , \circ) and outflow curve (\blacklozenge , \blacksquare , \bullet). Lower half of loop represents pressure-volume relationship during inflow portion of occlusion plethysmography and is strongly curvilinear with concavity-facing pressure axis. Outflow curve starts at maximum volume reached at end of inflow curve and traces from right to left. Note outflow of loop is less of a curve than inflow portion. Reproduced with permission from Neglen and Raju.³⁵⁷

occlusion plethysmography, and the EF. The findings of recent research are summarized here.

It has been demonstrated that patients with varicose veins present a constitutional decrease in venous α -adrenergic responsiveness,³⁶¹ affecting not only the compliance of the varicose veins themselves but also that of those apparently healthy veins. By using strain-gauge plethysmography, Clarke et al³⁶² demonstrated that the development of valve incompetence is probably secondary to reduced vein wall elasticity and increased arterial inflow. Postthrombotic legs are less compliant than normal legs mainly due to decreased compliance of the veins and surrounding tissues.³⁶⁰

Venotonic agents are able to decrease compliance and can be used clinically when the patient is experiencing discomfort because of venous hypertension.³⁶³ Dihydroergotamine is able to constrict not only normal but also varicose and postthrombotic veins.³¹⁶ Several studies that compared the clinical and plethysmographic activities of venotonic drugs with those of a placebo in patients with CVI (with or without varicose veins, or the postthrombotic syndrome) have demonstrated that after 1 or 2 months of treatment, an increase in venous tone was accompanied by improvement in symptoms and in edema.^{364,365} Szendro et al³⁶⁶ studied patients with varicose veins before and after they wore elastic stockings for 6 weeks. There was improvement in the air-plethysmographic measurements and elastic modulus calculated from the pressure-volume curve.

Methods for Study of the Microcirculation

Microvascular investigations have been used as research tools and have provided information regarding the pathogenesis of skin lesions in limbs with CVI. Their usefulness in clinical decision making has not yet been documented. However, because of their ability to detect early skin pathology, their prognostic value should be assessed in longitudinal studies.

Skin Biopsy

Skin biopsy samples can be taken from regions of interest through excision or punch biopsy. Different staining meth-

ods, including immunohistochemical, monoclonal antibody, or electron microscopic techniques, may be performed after fixation of the tissue. An indication for clinical use is the exclusion of malignancy in leg ulcers or in the diagnosis of skin changes when the underlying pathology is uncertain (eg, in vasculitis).^{367,368} In addition, biopsy has been extensively used as a research tool to study the pathophysiology of skin changes in CVI.

Complex structural changes have been described in capillaries, lymphatics, and dermal tissue in CVI. Capillaries are dilated, elongated, and tortuous. The endothelium is damaged and shows an irregular luminal surface, increased cytoplasmic, and dilated interendothelial spaces. The pericapillary space is enlarged to form "halos" from tissue edema. A glomerular-like appearance of "giant" capillaries that results from their elongation and distention is due to increased venous pressure and not to active proliferation, as can be demonstrated by the use of monoclonal antibodies (Ki-67) in the nuclei of proliferating endothelial cells.^{369,370} Changes in the pericyte envelope may also alter microvascular regulation and wound healing.³⁷¹ Hemoglobin from extravasated erythrocytes and erythrocyte fragments is degraded to hemosiderin, which is responsible for hyperpigmentation. Microthrombosis in capillaries causes microinfarction. Microvascular ischemia is patchy and leads to the formation of granulation tissue from fibroblast and capillary proliferation. Wound healing results in scar tissue, which destroys the microlymphatic network. Clinically, this process leads to lipodermatosclerosis and atrophy, and if compensating mechanisms are no longer able to repair the damage, ulceration ensues.^{369,372-374}

Capillaroscopy

Different methods of intravital capillaroscopy can be used to study the morphology and function of skin capillaries in various parts of the body.

Static capillaroscopy requires an ordinary light microscope.⁹⁴ For morphological studies, a magnification of $\times 5$ to $\times 100$ is appropriate. To enhance transparency, a drop of oil is applied to the skin area to be studied. Capillary loops can be easily identified in the nailfold because they run parallel to the skin surface, whereas only the apex of the loop can be observed in other parts of the body. Morphometric evaluation includes the measurement of capillary diameter, capillary density, and shape indices obtained with digital image processing.³⁷⁵

Dynamic videomicroscopy enhances capillaroscopy. Red blood cell velocity can be measured with a video system.³⁷⁶ A computerized technique of capillaroscopy allows the recording of blood cell velocity over longer periods of time.^{94,377}

Fluorescence videomicroscopy combines dynamic videomicroscopy with the intravascular injection of fluorescent dyes such as sodium fluorescein or indocyanine green.⁹⁴ It delineates microvascular structures such as the pericapillary space or lymphatic capillaries that are not visible with ordinary capillaroscopy. Moreover, it can study dynamic processes such as microvascular flow distribution and transcapillary or interstitial diffusion of small solutes.^{378,379}

These studies in patients with CVI show that the microvessels in areas with lipodermatosclerosis are dilated and coiled.

The number of perfused capillaries is reduced in severe disease, and capillaries are lacking in areas with "atrophic blanche." Transcapillary diffusion of small solutes is increased and pericapillary halos are enlarged as a result of papillary edema.^{96,380,381} Microvascular alterations are patchy, and skin areas with normal capillaries usually coexist with regions that demonstrate microangiopathy.

Capillaroscopy is a research tool. Although it has enlarged knowledge of the pathophysiology of venous ulceration, it is currently of limited value in the clinical management of patients with CVI.

Laser Doppler Fluxmetry

Laser Doppler fluxmetry (LDF) has been widely applied to assess local skin blood flow at various sites in human physiology studies and clinical medicine.³⁸² Most laser Doppler instruments use a narrow beam of monochromatic light in the red to near-infrared range that is delivered to and diffused into the skin via an optic light guide. Photons that encounter moving objects (primarily erythrocytes) undergo a Doppler frequency shift. The back-scattered light is processed and a voltage signal is produced that is directly proportional to the velocity and number of moving cells within the sample volume.^{383,384}

The technique is easy to use and provides a continuous and noninvasive measure of local blood flow, but to interpret the results, it is necessary to know its inherent limitations. The penetration depth of the laser light is assumed to be ≈ 1 to 1.5 mm, but variations in optical properties of the skin (thickness, pigmentation, and so on) will greatly influence the penetration depth and the reading. The small sample volume that is used leads to considerable signal variability at adjacent skin sites, thus introducing problems of reproducibility. Despite this, changes in the laser Doppler signal correlate well with measurements obtained through other methods.^{385,386} However, because of differences in sample volume and interinstrument variability, the results are displayed in arbitrary units for which the term "red cell flux" has been proposed.

Because of methodological limitations, LDF is best suited to assess relative changes of local blood flow in response to various stimuli such as arterial occlusion, orthostasis, or thermal stress or to evaluate spontaneous changes of blood flux over time (fluxmotion).³⁸⁷ Flux is markedly increased at rest in dermatosclerotic skin.^{91,369} Results of fluxmotion analysis are conflicting. Some authors found no changes in fluxmotion patterns in relation to the severity of the CVI,¹³⁵ whereas others reported an augmentation of fluxmotion frequency and amplitude.³⁸⁸ The physiological decrease in skin flow in response to lowering the foot (postural vasoconstriction) may be diminished in severe CVI.^{91,389} Because LDF mainly represents blood flow from the subcapillary level, these findings indicate hyperperfusion in affected skin areas in the deeper, nonnutritive microcirculation that persists during sitting and standing. LDF has also been used to evaluate the effect of compression therapy on local skin blood flow. It has been demonstrated that elastic compression for several weeks or intermittent pneumatic compression for

several hours tends to normalize the high red cell flux found in limbs with CVI and to induce normal vasomotion.^{91,390}

Currently, LDF is an important technique for clinical microvascular research, but its application to routine clinical practice is limited.^{390,391}

Transcutaneous Oxygen Tension

Transcutaneous oxygen tension (TcPO₂) is measured with a polarographic technique. The electrode is heated to 45°C to induce local skin hyperemia. TcPO₂ can be defined as a measure of the surplus of oxygen molecules available for diffusion to the skin surface from the capillaries of the papillae under hyperemic conditions (expressed in mm Hg). Approximately 10 to 15 minutes is required to establish a steady-state condition. With a transparent TcPO₂ electrode, capillary microscopy and TcPO₂ measurements may be performed simultaneously.⁹² A recent development is the incorporation of a laser Doppler probe.³⁹²

Patients with CVI and morphological changes in blood capillaries but without a reduction in capillary numbers already exhibit a significantly decreased TcPO₂.^{92,393} Patients with more severe stages of CVI show a further decrease in TcPO₂, which is linearly related to a reduction in capillary density. TcPO₂ may even approach zero in areas of "atrophic blanche," indicating microvascular ischemia at these skin sites where blood-filled capillaries are totally lacking.⁹²

TcPO₂ measurements are of limited value for the clinical management of patients with CVI, but the technique is of great interest for studying the pathophysiology involved in the development of skin changes and ulceration.

Fluorescence Microlymphography

Fluorescence microlymphography is the only method available that can analyze structure and function of the initial lymphatics in the skin in humans in vivo. To stain the lymphatic microvessels, 0.01 mL of a 25% solution of fluorescein isothiocyanate (FITC)-dextran (molecular weight 150 000) is injected subepidermally with a microneedle (external diameter 0.2 mm) and a microsyringe.³⁷⁹ FITC-dextran is mainly cleared by lymphatics, because it has a high molecular weight. The small size of the needle and minute volume injected guarantee that the puncture causes only minimal discomfort to the patient. The subepidermal depot is visualized with incident light fluorescence microscopy. The network of lymphatic capillaries is filled from this depot. The dynamics of dye spread into the network, the extension of the dye, and the morphology of the lymphatic network are observed and documented on tape recordings or photographically with high-speed fluorescence-sensitive film. Microlymphatic flow velocity can be determined during the filling of the superficial capillary network.³⁹⁴ Fluorescence microlymphography is virtually atraumatic and easily performed within 15 to 30 minutes.

Microlymphatic morphology is essentially normal in patients with CVI but without trophic skin changes,¹⁰⁷ although the propagation of the dye into the superficial network is increased. However, definite microangiopathy is visible in skin areas, with induration and hyperpigmentation. Some network meshes are interrupted; and fragments of capillaries are stained far away from the dye deposit, probably due to

TABLE 11. Lymphoscintigraphy: Components of Transport Index

	Score			
	0	3	5	9
Transport kinetics	No delay	Mild delay	Extreme delay	No flow
Distribution patten	Normal	Partial dermal	Diffuse dermal	No flow
Time index	Time in minutes for appearance of regional lymph nodes, multiplied by 0.04			
Lymph nodes	Normal	Visible, diminished	Barely visible	Not seen
Lymph vessels	Normal	Visible, diminished	Barely visible	Not seen

From Kleinhans et al.⁴¹⁵

valvular insufficiency and retrograde flow in collectors and precollectors^{107,394}; and there is increased macrovascular leakage from the damaged microvessels.³⁷⁸

Fluorescence microlymphography is able to confirm the presence of lymphatic microangiopathy that contributes to lipodermatosclerosis. The technique is most valuable for clinical research into the pathophysiology of edema and skin changes in patients with CVI.¹⁰⁸

Interstitial Pressure Measurements

Pressure measurements in the microcirculation and surrounding tissues became possible in the 1960s with the servonulling pressure system developed by Wiederhielm et al³⁹⁵ with further modifications by Intaglietta et al.³⁹⁶ In humans, pressure has been successfully determined in nailfold capillaries,³⁹⁷ microlymphatics,^{398–400} and the interstitium.⁴⁰⁰

Interstitial pressure can be measured in 2 phases. In phase 1, the investigator visualizes the microcirculatory unit through a video microscope after staining with a subepidermal injection of FITC-dextran (molecular weight 150 000). In phase 2, the interstitial pressure is determined by introducing a glass micropipette 2 μm in diameter connected to a servonulling pressure system.^{401–403} The tracing of the interstitial pressure is almost a flat line without the typical pressure waves recorded in capillaries or in microlymphatics.⁴⁰⁰

The measurement of interstitial pressure is useful in the study of the evolution of the disease but as yet has no clinical application. The limitations of the method are the high cost of the equipment and the need to train operators, with at least 2 needed for this very delicate technique.

Lymphoscintigraphy

Lymphoscintigraphy with radioactive plasma protein to evaluate patients with lymphedema was first reported in the 1950s.⁴⁰⁴ Because of improved imaging and a better selection of optimal size of the labeled particles, there has been a continuous improvement in the past 2 decades.^{405–411} Significant experience has accumulated with technetium-99 antimony trisulfide colloid^{409,412,413} and ^{99m}Tc-human serum albumin.⁴⁰⁷ The optimal size of particles for delineation of lymph vessels and lymph nodes in extremity lymphoscintigraphy is between 10 and 40 nm.

About 0.1 to 0.2 mL of the radiolabeled colloid (350 to 450 μCu) is injected into the web space between the second and third toes with a tuberculin syringe and a 27-gauge needle. A gamma-camera with a large field of view is positioned to include the inguinal region. Exercise with a foot ergometer

starts immediately after the injection. The patient exercises for 5 minutes and then for 1 of every 5 minutes for the remainder of the first hour. Dynamic anterior images are obtained every 5 minutes during the first hour. Total body images over 20 minutes are obtained at 1 and 3 hours after the injection. Six- and 24-hour total body images are obtained in selected patients.

Lymphatic function can be assessed qualitatively from visual interpretation of scintigraphic images. Semiquantitative interpretation includes the measurement of the appearance time of radioactivity in regional lymph nodes during dynamic imaging. Quantitative interpretation includes the measurement of colloid clearance from the injection site or its appearance at the groin.⁴¹⁴ A semiquantitative scoring system was initially described by Kleinhans et al⁴¹⁵ in which the “transport index” was graded from 0 for scans with normal transport to a maximum of 45 for scans with no evidence of lymphatic transport. In this scoring system, lymphatic transport kinetics, isotope distribution pattern, lymph node appearance time, assessment of lymph nodes, lymph vessels, and sites of abnormal tracer accumulation are assessed and scored (Table 11).

Significant activity in major regional nodes within 15 minutes indicates rapid lymphatic transport, and the absence of activity at 1 hour suggests delayed transport. Early visualization of the liver without activity in lymph nodes suggests that the injection of the tracer was intravenous. Lymphoscintigraphic findings in patients with venous disorders may vary depending on the chronicity of the disease.

Increased lymphatic transport is evident in acute venous occlusion when capillary filtration and edema in the extremity increase,⁴¹⁶ but delayed transport may be seen in some patients with chronic venous disease.^{413,416} The site of the injection also affects results.⁴¹⁷ The injection of tracer into an ulcer border may result in a decreased or absent uptake in the lymph nodes, whereas injection into the toe web may lead to increased uptake.^{417,418}

Cambria et al⁴¹³ reported a prospective evaluation of the transport index in 386 extremities. The average transport index for asymptomatic extremities was 2.6; the value was 23.8 for lymphedematous limbs. A transport index of >5 was highly suggestive of lymphedema (sensitivity 80% and specificity 94%) but could not be used to distinguish between primary and secondary lymphedema. Lymphoscintigraphy excluded lymphatic pathology as a cause of extremity swelling in one third of the cases. Other authors also recommend time-activity curves from dynamic imaging over lymph nodes

TABLE 12. Published Classifications of Chronic Venous Disease

Author	Year
Widmer ⁹	1978
Hach et al ⁴¹⁹	1980
Partsch ⁴²⁰	1980
Molokhia ⁴²¹	1981
Sytchev ⁴²²	1985
Pierchalla and Tronnier ⁴²³	1986
Porter et al ⁴²⁴	1988
Cornu-Thenard et al ⁴²⁵	1991
Enrici and Caldevilla ⁴²⁶	1992
Miranda et al ⁴²⁷	1993
Nicolaides et al (CEAP) ⁴²⁸	1995
Porter and Moneta ⁴²⁹	1995

to analyze lymphatic function.⁴¹⁰ However, Gloviczki et al⁴¹² showed that this was highly variable in normal extremities, so it was difficult to interpret the data. It appears that it is sufficient to use visual interpretation of images and the semiquantitative transport index to describe lymphatic transport. Contrast lymphangiography is the gold standard, but it has been performed in very few patients in most published series, so the true sensitivity and specificity for lymphoscintigraphy are not well defined.

Lymphoscintigraphy has now become established as the principal noninvasive technique for the evaluation of patients with chronic lymphedema. It is also suitable for the assessment of lymphatic function in patients with chronic venous disease. However, further studies are needed to demonstrate the ability of the lymphatic system to compensate for the effects of CVI by increasing lymphatic drainage and to determine whether the symptoms are made worse if lymphatic drainage is inadequate.

Measurement of Clinical Parameters

CEAP Classification of CVI

A classification system is a basic tool for uniform diagnosis and meaningful scientific communication on CVI. For too long, reliance has been placed on the clinical appearance of the superficial effects of CVI, such as varicose veins, skin changes, and ulceration, without requiring accurate objective testing of the venous system to substantiate the diagnosis. This practice has caused errors of diagnosis and has been

TABLE 13. CEAP Classification

C	Clinical signs (grades 0 to 6), supplemented by A for asymptomatic and S for symptomatic presentation
E	Etiologic classification (congenital, primary, secondary)
A	Anatomic distribution (superficial, deep, or perforator, alone or in combination)
P	Pathophysiological dysfunction (reflux or obstruction, alone or in combination)

TABLE 14. CEAP Clinical Classification (C)

Class	Clinical Indication
0	No visible or palpable signs of venous disease
1	Telangiectases or reticular veins
2	Varicose veins
3	Edema
4	Skin changes ascribed to venous disease (eg, pigmentation, venous eczema, lipodermatosclerosis)
5	Skin changes as defined here with healed ulceration
6	Skin changes as defined here with active ulceration

largely responsible for the poor correlation of results between different treatment regimens.

There have been several classifications^{9,419–429} (Table 12) and severity scoring systems⁴³⁰ in the past that have added to our understanding of venous disease, but all lack the completeness and objectivity needed for scientific accuracy. The 1988 report of the Joint Council of the SVS/ISCVS was a step forward in addressing the cause and pathogenesis of CVI in a more organized way.⁴²⁴ The consensus report of the American Venous Forum in 1994 presented the CEAP classification, which addressed the clinical, etiological, anatomic, and pathophysiological mechanisms of CVI with the need for objective testing. This CEAP classification was the basis for the chronic venous portion of an SVS/ISCVS update on reporting standards by Porter and Moneta.⁴²⁹ It presents a new level of diagnosis in CVI but requires a change of habit for the physician. The requirements for CEAP are similar to those customarily followed in the diagnosis of arterial disease where it would be unthinkable to treat without knowing the cause (atherosclerosis or embolism), the anatomic distribution (iliac or femoral), and the pathophysiology (occlusion or stenosis). Relying on the clinical diagnosis alone for chronic venous disease would be the equivalent of trying to treat arterial disease by prescribing various medications after simply looking at the ischemic toe.

The CEAP classification is contained in Tables 13 through 17 with abbreviations conveniently expressed for easy and rapid presentation. For example, a patient with symptomatic varicose veins that extend throughout the whole territory of the long saphenous vein and with swelling, pain, and lipodermatosclerosis associated with incompetent perforators in the calf with a normal deep system as shown by investigations is denoted C2,3,4s - Ep - As2,3,p18 - Pr. In addition, the consensus report describes methods of both severity scoring for the disease process and a disability rating for the patient (Tables 18 and 19). These make it possible to record a patient's condition at a given time that may then be altered with treatment so it can provide a measure of the efficacy of

TABLE 15. CEAP Etiological Classification (E)

Congenital	E _c
Primary	E _p : with undetermined cause
Secondary	E _s : with known cause (postthrombotic, posttraumatic, other)

TABLE 16. CEAP Anatomic Classification (A)

Segment No.	Superficial veins (A _s)
1	Telangiectases/reticular veins Greater (long) saphenous
2	Above knee
3	Below knee
4	Lesser (short) saphenous
5	Nonsaphenous
6	Deep veins (A_d) Inferior vena cava Iliac
7	Common
8	Internal
9	External
10	Pelvic—gonadal, broad ligament, other Femoral
11	Common
12	Deep
13	Superficial
14	Popliteal
15	Crural—anterior tibial, posterior tibial, peroneal (all paired)
16	Muscular—gastrocnemial, soleal, other Perforating veins (A _p)
17	Thigh
18	Calf

the treatment protocol. In this way, the CEAP classification can be used over time as a tool to measure change.

Practical use of the CEAP classification does not demand that every patient undergoes the full gamut of diagnostic investigations. A simple problem such as telangiectasia is always primary in cause and superficial in location. It is not concerned with a pathophysiological change in major veins, so a simple designation of C1 (a or s) is sufficient to show that the clinical problem is telangiectasia modified by whether it is symptomatic. Varicose veins (C2) may also be a simple clinical problem that is usually associated with reflux but can present many variations of differing causes, anatomically always superficial but varying from the greater to the lesser saphenous systems. The diagnosis requires the hand-held Doppler and is frequently improved with duplex scanning. Determination of the hemodynamic severity will require plethysmographic or pressure studies. Phlebography or varicography can help to map disease before or during surgery, although they are not indicated for the routine diagnosis of superficial varicose disease. As the severity progresses to C3 and above, vascular laboratory investigations become mandatory.

CEAP has been promulgated around the world. It has been published in 23 separate journals and books in 8 languages

TABLE 17. CEAP Pathophysiological Classification (P)

Reflux	P _R
Obstruction	P _O
Reflux and obstruction	P _{R,O}

TABLE 18. CEAP Clinical Score (C)

Pain	0, none; 1, moderate, not requiring analgesics; 2, severe, requiring analgesics
Edema	0, none; 1, mild/moderate; 2, severe
Venous claudication	0, none; 1, mild/moderate; 2, severe
Pigmentation	0, none; 1, localized; 2, extensive
Lipodermatosclerosis	0, none; 1, localized; 2, extensive
Ulcer—size (largest ulcer)	0, none; 1, <2-cm diameter; 2, >2-cm diameter
Ulcer—duration	0, none; 1, <3 mo; 2, >3 mo
Ulcer—recurrence	0, none; 1, once; 2, more than once
Ulcer—number	0, none; 1, single; 2, multiple

and in 5 continents (Table 20). Given this wide exposure, general adoption should occur when sufficient researchers are educated as to its advantages and begin to use it for their publications. A criticism has been raised that CEAP is too complex, but the alternative of continuing to work with inadequate diagnostic criteria is unacceptable. There is a need to educate those who publish CVI subjects regarding its advantages, while working to find an acceptable format. Several groups that have used it have found it valuable and practical.^{431–434}

Although the CEAP classification provides a system for documentation of the severity of CVI, it is often necessary to evaluate individual symptoms, signs, or physiological parameters; clinical outcome; and quality of life. The available methodology is summarized here.

Pain

The assessment of pain is subjective but can be evaluated with analog scales and analgesic requirements.

Varicose Veins

Telangiectasia, reticular veins, and varicose veins can be assessed visually with photographs and diagrams.⁹

Lipodermatosclerosis

The degree of induration caused by lipodermatosclerosis can be measured with different techniques, including a 20-MHz ultrasound B-scan,⁴³⁵ a “durometer,”⁴³⁶ and a tissue compliance monitor.⁴³⁷

Edema and Leg Volume

Volumetry to measure leg volume is an old⁴³⁸ but recently updated noninvasive technique. Volumetry does not quantify edema but rather the short-term variations that reflect changes in edema. It can only show changes for each individual. It is reproducible provided measurement conditions are carefully standardized.

TABLE 19. CEAP Disability Score

0	Asymptomatic
1	Symptomatic, can function without support device
2	Can work 8-h day only with support device
3	Unable to work even with support device

TABLE 20. Journals and Books in Which the CEAP Classification Has Been Published

<i>Actualités Vasculaires Internationales</i> 1995;31:19–22
<i>Angiology</i> 1995;47:9–16
<i>Angiology News</i> 1996;19:4–6
<i>Australia and New Zealand Journal of Surgery</i> 1995;65:769–772
<i>Dermatologic Surgery</i> 1995;21:642–646
<i>Elleniki Angiokirurgiki</i> 1996;5:12–19
<i>European Journal of Vascular and Endovascular Surgery</i> 1996;12:487–491
<i>Forum de Flebologia y Limfologia</i> 1997;2:67–74
<i>Handbook of Venous Disorders</i> 1996;652–660
<i>International Angiology</i> 1995;2:197–201
<i>Japanese Journal of Phlebology</i> 1995;1:103–108
<i>Journal of Cardiovascular Surgery</i> 1997;38:437–441
<i>Journal of Vascular Surgery</i> 1995;21:635–645
<i>Journal des Maladies Vasculaires</i> 1995;20:78–83
<i>Mayo Clinic Proceedings</i> 1996;71:338–345
<i>Minerva Cardioangiologica</i> 1997;45:31–36
<i>Myakkangaku</i> 1995;35:1–6
<i>Phlébologie: Annales Vasculaires</i> 1995;48:275–281
<i>Phlebologie</i> (German version) 1995;24:125–129
<i>Phlebology</i> 1995;10:42–45
<i>Przegląd Flebologiczny</i> 1996;4:63–73
<i>Scope on Phlebology and Lymphology</i> 1996;3:4–7
<i>VASA</i> 1995;24:313–318
<i>Vascular Surgery</i> 1996;30:5–11

Volumetry allows an accurate comparison of changes in the same leg over time or with changing conditions as displayed by different amounts of edema (eg, morning versus evening, supine versus standing, resting versus after exercise, before versus after the application of a venous tourniquet, before versus after treatment, and at the beginning versus at the end of the follow-up period). In a recent consensus meeting, international experts considered volumetry to be the gold standard to prove and compare the efficacy of any treatment to reduce edema in CVI.⁴³⁹

The leg is immersed in a Plexiglas boot. The displaced water is collected, and its volume is measured.^{440,441} Other techniques have been described but are performed in a nonphysiological state: the supine position.^{442–448} Three parameters must be standardized: the position of the leg, the hour of measurement, and the water temperature. The accuracy of the method is 0.7% for 2 consecutive measurements in the same leg by 2 different observers; its intraindividual repeatability is 1.3%; and its interindividual variability is 6.2% in normal control subjects and 11.2% in patients with CVI.⁴⁴¹

Volumetry has been used to prove that legs that ache are those that swell the most,⁴⁴⁹ that leg volume increases during daily activity and that this increase correlates with the severity of CVI,⁴⁵⁰ and that leg volume may increase during long distance flights⁴⁴⁸ and that it diminishes after venous surgery⁴⁵¹ and after different drug treatments for venous or lymphatic insufficiency.^{452–455} Studies are now in progress to

test whether changes in leg volume correlate with the severity and prognosis of CVI.

Other methods of measuring edema include leg circumference measurements with tape,^{454,456} electro-optic volumetry,^{444,446,447,457} and computerized limb volume measurements.⁴⁴⁵

Calf Muscle Pump Function

Calf pump failure is a concept that was introduced in the 1960s⁴⁵⁸ and further developed in the 1980s.⁴⁵⁹ The action of calf muscles on deep venous return has been compared with that of the heart muscle, and reproducible measurements of its efficacy are now possible.^{284,460} However, anatomic prerequisites for the calf pump system to function properly are often neglected in the clinical evaluation of CVI. A deficient calf pump is probably the key factor for the high rate of CVI among elderly persons.^{461,462} A normal plantar arch, normal ankle mobility, and normal painless calf muscle action are required for normal venous calf pump function. Clinical evaluation of CVI should therefore include assessment of the ankle joint¹³⁵ and check for the presence of any associated muscular, articular, or neurological disease.⁴⁵⁹

Ulcer Healing

To quantify ulcer healing for clinical trials, it is necessary to develop methods to calculate and standardize the ulcer geometry and to define appropriate endpoints. The area of the ulcer can be measured with planimetry, with its outline drawn on a transparent sheet, with scaled photography, or with direct ultrasonic digitized measurements with a light pen.⁴⁶² Alternatively, it can be calculated by multiplying the 2 maximal perpendicular diameters to obtain an area in cm². If this is then multiplied by $\pi/4$, the calculated rectangular area is transformed to an elliptic one. Gillman⁴⁶³ published a method for the calculation of wound-healing rates that corrects for differing sizes and shapes by dividing the area of the ulcer by its perimeter.

The changes in the geometrical measurements per unit time mentioned earlier are often used in clinical trials.^{464,465} However, complete healing and the initial healing rate are the most common end points used.^{26,466,467} Complete healing is quantified either by the time taken to achieve it for each ulcer or by calculating the percentage of ulcers healed during a finite period of time. The initial healing rate is defined as the rate of healing over the course of a first time period, such as the first 4 weeks. With Gillman's equation (A/P) and considering the change of the ulcer area corrected for size, the healing rate per unit time is derived as $\Delta A/P_{(a-b)} = (A_b - A_a) / [(P_a + P_b)/2](b - a)$, where A is the area of the ulcer, P is its perimeter, a is the start of the observation period, and b is its end.

Percentage of area decrease per unit time is not a valid end point, because this depends on the size of the ulcer.⁴⁶⁴ However, the Gillman equation corrects for different initial ulcer sizes, so it meets the needs of clinical studies for standardized and comparable measurements.^{466,468,469} From the patient's point of view, "complete healing" is the most important outcome, although from the practical point of view, the "initial healing rate" seems to be more suitable for

reporting results. Possibly, a combination of both should be used.

Cumulative rates can be used for studies with adequate numbers of patients. The proportion of ulcers that healed in the North American Subfascial Endoscopic Perforator Surgery (NASEPS) study was estimated with the life table analysis.⁴³³ A cumulative distribution function for the period from the time of an intervention such as surgery to healing can also be used to determine its rapidity. In addition, long-term follow-up studies can use cumulative ulcer-free survival time to document the recurrence rate for venous ulcers.

Evaluation of Clinical Outcome

The best way to assess the clinical outcome after treatment for chronic venous disease depends to a great extent on the clinical presentation. As indicated earlier, it is difficult to evaluate improvement in cosmetic appearance or subjective symptoms such as cramps, itching, pain, or fatigue. Also, the patient's preference and acceptance of different treatments must be considered.

Symptoms can be evaluated by the clinician or by patient self-report. In the latter case, a questionnaire should be completed at leisure outside the physician's office. This method is used most frequently for evaluation before, during, and after treatment. Patients can be asked to provide global ratings of improvement in symptoms⁴⁷⁰ or to use quantitative scales such as a Likert scale^{471,472} or a visual-analog scale.⁴⁷³

It is much easier to accurately measure improvement in clinical signs, such as diminishing size, healing, or recurrence of an ulcer or change in the circumference or volume of the extremity, than to evaluate symptoms.

The efficacy of treatment is best established through the documentation of improvement in signs and symptoms, supported if possible with laboratory tests; recording of all adverse effects of treatment; and a follow-up of at least 6 months and preferably 1 year.

The updated CEAP classification of CVI that assigns patients into 1 of 7 clinical categories (C₀₋₆) based on increasing severity of clinical symptoms and signs should be used. All patients should be assigned a CEAP clinical class before and after treatment. A lower clinical class after treatment represents clinical improvement.

A clinical scoring system to assess severity was suggested by the Consensus Committee of the American Venous Forum on Chronic Venous Disease. This system scores the severity of pain, edema, venous claudication, pigmentation, and lipodermatosclerosis; ulcer size, duration, and recurrence; and number of ulcers (Table 18). An example of this system is the assessment of the outcome of operations on superficial and perforating veins assessed in a recently published study on the early results of the NASEPS registry.⁴³³ The researchers analyzed patients who underwent endoscopic perforator interruption to treat advanced chronic venous disease. Seventy percent had active ulcerations and 72% had surgery on the superficial veins in addition to perforator interruption. The average clinical score was 9.4 (range 0 to 18) before surgery and decreased to 2.9 after surgery (range 0 to 12, $P=0.0001$) (Table 21).

Adverse effects from treatment must be recorded. Complications from surgery or sclerotherapy such as death, wound infection, superficial thrombophlebitis, cellulitis, and saphenous neuralgia should be reported.

The level of disability before and after treatment can also be assessed with a disability score as suggested by the CEAP Consensus Committee (Table 19). This scoring system evaluates functional outcome and the ability to return to work with or without a support device. Patient compliance with conservative measures, such as elastic stockings, a compression pump or leg elevation, should be accurately recorded by a physician.

The reliability, accuracy, and validity of the different scoring systems need further evaluation.

Quality of Life

Quality of life in patients with CVI has been assessed with generic and with disease-specific measures. These studies were recently analyzed in detail.² The most frequently used generic measure is the Medical Outcome Study Short Form Health Survey (SF-36), a 36-item questionnaire that covers 8 health dimensions, including physical and social functioning, role limitations due to physical and emotional problems, mental health, vitality/energy, bodily pain, and general health perceptions. The SF-36 has been used both in patients with varicose veins and in those with venous ulcers.^{474,475} In the study by Garratt et al,⁴⁷⁴ SF-36 satisfied strict psychometric criteria for validity and internal consistency and confirmed a significantly lower quality of life in patients with varicose veins compared with an age-adjusted sample from the normal population.

Because specific complaints from patients with chronic venous disease were not identified with currently used generic quality-of-life questionnaires, specific questionnaires were developed to assess the functional and psychological effects of venous disease.^{25,476,477} The most recent of these is the Chronic Venous Insufficiency Questionnaire (CVIQ) used by Launois et al.⁴⁷⁷ The questionnaire has been validated and found to meet stringent psychometric criteria, including reliability, content, construct validity, and responsiveness. In a randomized trial of 934 patients, the CVIQ showed that quality-of-life scores were significantly lower in patients with venous insufficiency than in control subjects without venous disease.

Health-related quality-of-life studies should be used in the future to assess overall outcome and to justify treatment for chronic venous disease. Both generic and venous disease-specific measures should be used.

Application of Methods in the Investigation of Chronic Venous Insufficiency

General Remarks

The second part of this document demonstrates how different tests provide different information. There is no one test that can provide all of the information needed to make clinical decisions and to plan a management strategy. By asking and answering relevant clinical questions, more information becomes available and the diagnosis becomes more precise. What is needed is clear knowledge of the tests required to

TABLE 21. Scoring System for CVI and an Example of Mean Clinical Scores Before and After Surgical Treatment in 114 Limbs

Category	Scoring System	Mean Preoperative Score	Mean Postoperative Score
Pain	0, None		
	1, Moderate, not requiring analgesics	1.14	0.22
	2, Severe, requiring analgesics		
Edema	0, none		
	1, Mild/moderate	0.94	0.43
	2, Severe		
Venous claudication	0, None		
	1, Mild/moderate	0.15	0.04
	2, Severe		
Pigmentation	0, None		
	1, Localized	1.29	0.99
	2, Extensive		
Lipodermatosclerosis	0, None		
	1, Localized	1.02	0.69
	2, Extensive		
Ulcer size: (largest ulcer)	0, None		
	1, <2-cm diameter	1.26	0.18
	2, >2-cm diameter		
Ulcer: duration	0, None		
	1, ≤3 mo	1.39	0.20
	2, ≥3 mo		
Ulcer: recurrence	0, None		
	1, Once	1.24	0.04
	2, More than once		
Ulcer: number	0, None		
	1, Single	1.00	0.15
	2, Multiple		
Total mean clinical score*		9.43	2.94

Patients with both preoperative and postoperative clinical scores are reported.

From Gloviczki et al⁴³³

* $P < 0.005$.

arrive at the correct clinical diagnosis with the minimum expense and inconvenience to the patient. Noninvasive venous investigations are performed by vascular technologists (or physicians) who are trained to apply the proper tests to provide answers to the key questions required by the clinician. The aim of the third part of this document is to demonstrate how venous investigations can be applied for both clinical management and research.

A number of clinically relevant questions should be asked by a physician when a patient presents with symptoms and signs suggestive of CVI. Is there any CVI present? If there is, is it the result of obstruction, reflux, or both? What is the anatomic extent of the obstruction or reflux? What is the severity of the obstruction, and what is the severity of the reflux? Is there a calf muscle pump failure due to a musculoskeletal problem? What is the combined hemodynamic effect of obstruction, reflux, and

calf muscle pump failure? Are the abnormalities that are found responsible for the clinical picture, and are they fully responsible, or are there any other contributory factors? What is the prognosis for the patient? What information is needed to make the correct therapeutic decision, and what is the way to obtain the information in the most efficient manner? How should the therapeutic results be evaluated?

Detection of Reflux and Obstruction

The initial evaluation of patients with CVI consists of determining the presence or absence of reflux, obstruction, or both. As stated in the first part, the history and clinical examination will indicate the clinical presentation. The use of a pocket Doppler ultrasound by the physician in the outpatient department can provide information to elicit the presence of reflux at the saphenofemoral junction, popliteal fossa,

and superficial veins and obstruction at the femoropopliteal or iliofemoral segments in 80% to 90% of patients. A proportion of patients (20% to 30%) have more complicated conditions and will require further investigation. Many will have had a previous operation on their veins or unclear results of their Doppler ultrasound test. Those with reflux in the veins of the popliteal fossa and the group in whom incompetent calf perforating veins are suspected will require further clarification.

Localization of Reflux and Obstruction

In the past, a phlebogram was required to localize venous obstruction, but duplex scanning has proved to be equally effective, particularly for lesions distal to the common femoral vein. Phlebography also can be accurately used to localize the sites of deep-to-superficial reflux (saphenofemoral, saphenopopliteal, incompetent perforating veins) and the extent of reflux in the deep veins. Duplex scanning is proving to be simpler and more accurate, so ascending and descending phlebograms are now rarely performed. The main indication for descending phlebography is the detection of incompetent valves with floppy cusps in the deep veins. Preoperative duplex scanning is the method of choice to localize the sites of incompetent perforating veins and the level of the saphenopopliteal junction, which is extremely variable. As a result, the position of the incision in the popliteal fossa can be precise.

Quantification of Reflux and Obstruction

Quantitative measurements of outflow obstruction and reflux may be needed for research, particularly in the study of the natural history of CVI, and for the assessment of established and new methods of treatment. These quantitative measurements have opened new avenues that lead to a better scientific basis for patient management. Until recently, AVP measurement was the only quantitative test available. Although it is invasive, it indicates the severity of venous hypertension as it measures the end result of both reflux and outflow obstruction. However, new noninvasive tests, such as air-plethysmography, can distinguish the relative contributions from venous obstruction, reflux in the superficial or deep veins, and calf muscle pump function, whether the result of intrinsic venous disease, a musculoskeletal problem, or both.^{288,478}

Investigation of Patients in Different CEAP

Clinical Classes

A simple method of selecting the appropriate tests is to grade the diagnostic investigations into 3 levels:

Level I involves the clinical examination (history, physical examination that includes an evaluation of the arterial circulation, and venous examination with the hand held Doppler).

Level II involves noninvasive investigations (duplex scanning, plethysmography).

Level III involves invasive investigations (ascending and descending phlebography, varicography, pressure measurements).

A simple guide to the level of investigation in relation to CEAP clinical classes (Table 14) is given here; this may be modified according to clinical circumstances and local practice.

Class 0/I: No Visible or Palpable Signs of Venous Disease; Telangiectases or Reticular Veins

Level I investigations are usually sufficient. However, symptoms such as aching, heaviness, and leg-tiredness in the absence of visible or palpable varicose veins are an indication for duplex scanning to exclude reflux in the saphenofemoral, saphenopopliteal, or gastrocnemial veins, which often precedes the clinical manifestation of varices; Also, duplex screening should be performed to exclude proximal chronic deep venous occlusion, which, in the presence of competent popliteal valves, will not produce any skin changes or ankle edema.

Class 2: Varicose Veins Present Without Any Edema or Skin Changes

Level I may be sufficient, but level II (duplex scanning) should be used in many practices as indicated later. Level III may be needed in special cases.

Level I investigations are sufficient in patients with varicose veins confined to the long saphenous system on hand-held Doppler with reflux at the saphenofemoral junction and absence of reflux in the popliteal fossa and whose varicosities are controlled by pressure at the saphenofemoral junction or by a high thigh tourniquet. Many patients with primary varicose veins fall into this category.

Varicose veins that involve the short saphenous system, reflux in the popliteal fossa on hand-held Doppler, or suspected incompetent thigh or calf perforating veins because the varicosities are not controlled by a high thigh or below knee tourniquet, respectively, are indications for duplex scanning. In such circumstances, duplex scanning provides essential information for management by identifying the anatomic site of reflux in the popliteal fossa (short saphenous, gastrocnemial, or popliteal). Duplex scanning is also used to mark the position of incompetent perforators and the level of the saphenopopliteal junction before surgery.

Patients with recurrent varicose veins and those with a history of documented or possible DVT must be investigated with duplex scanning. Air-plethysmography to estimate the outflow fraction (OF_1) is often used as a screening test to exclude functional obstruction. Level III investigations may be considered if a duplex scan shows deep venous reflux or obstruction.

The presence of varicose veins filling from unusual sites such as a lateral thigh incompetent perforator or vulvar veins is also an indication for duplex scanning. Filling of the varicose veins in the thigh and leg from vulvar veins may be an indication for descending ovarian phlebography.

Class 3: Edema With or Without Varicose Veins and Without Skin Changes

Level II investigations are used to determine whether reflux or obstruction in the deep veins is responsible for the edema. If obstruction is demonstrated or suspected as a result of duplex scanning, the use of plethysmography will grade its

severity. In the presence of isolated edema if level II investigations are abnormal, level III investigations of the deep venous system must be considered. If venous investigations are normal, lymphedema is the most likely diagnosis. If the diagnosis is in doubt, lymphoscintigraphy may be necessary.

Class 4/5/6: Skin Changes Suggestive of Venous Disease, Including Healed or Open Ulceration With or Without Edema and Varicose Veins

Level I and II investigations will be required in the majority of these patients. Selected cases, mainly candidates for deep venous reconstruction, will proceed to level III.

Level I investigations may be sufficient in some patients with irreversible muscle pump failure due to neurological disease or severe and noncorrectable reduction of ankle movement or where there is a contraindication to surgical intervention. Some investigations may have to be deferred, particularly in patients with painful ulcers. Most patients will be subjected to level II investigation. Candidates for deep venous reconstruction will require level III.

Assessment of the Effect of Different Therapies

Compression

The pressure exerted on the leg with compression devices should be measured at different levels to show the proximal and distal pressure gradients at various time intervals and with the assumption of different bodily positions.

The clinical outcome of ulcer healing and rates of recurrence can be used to assess the effect of compression therapy. One reliable method is to measure the proportion of patients whose venous ulcers heal within 8 to 12 weeks.^{29,479–485} Another method is to record the diminution of a radius per unit time. The latter is more valid than the widely used percentage area reduction because it is independent of the initial ulcer size.^{463,464,486} The recurrence rate after healing is an important indicator of efficacy and patient compliance.^{89,487–491}

Reduction in edema can be measured with tape,^{456,492} with volumetric methods such as water displacement, or with the use of optoelectronic instruments.^{441,442,445,447,455}

The narrowing of veins through compression can be demonstrated with phlebography⁴⁹³ and with duplex.^{29,494–496} Reduction in venous volume can be demonstrated with air-plethysmography.^{280,297,366,497} A shift of blood volume from the compressed extremity toward central regions of the body can be shown with labeled red blood cells.^{316,498}

Reduction in venous reflux is an important effect of compression. It has been measured in the past with PPG⁴⁹⁹ and more recently with air-plethysmography.²⁹⁸ An increase in venous return may be demonstrated by injecting radioactive tracers into a dorsal foot vein and measuring the transit time in the compressed extremity.³¹¹ Duplex investigations for both reduction in reflux and increase in venous return have revealed equivocal results,^{29,494,496} probably due to methodological problems.

An improvement in venous pumping with elastic compression can be shown with foot volumetry,^{311,314,500,501} strain-gauge plethysmography,^{495,502} or air-plethysmography.^{280,298,497,503} The

literature is equivocal concerning the effect of compression on AVP.^{29,280,311,500,504} but this may be because of the different compression bandages that are used.

The effect of elastic compression on the skin microcirculation can be shown by laser Doppler fluxmetry,^{390,505–507} transcutaneous oxygen measurement,^{506–508} and skin biopsies.⁵⁰⁹ A reduction in arterial inflow toward normal can be demonstrated with clearance techniques and with plethysmography.^{299,510,511}

The influence of compression on lymphatic drainage in CVI is a widely underestimated effect that can be assessed with lymphoscintigraphy, fluorescence microlymphography, and microlymphatic pressure measurements.^{512–515}

Intermittent sequential pneumatic compression in combination with elastic compression increases the rate of ulcer healing far more than elastic compression alone,⁴⁸² but the precise mechanism is not known. There is a marked reduction in laser Doppler flux and an improvement in vasomotor activity within minutes after its application.³⁸²

Medication

Although the effect of drugs on physiological parameters such as venous tone, venous hemodynamics, capillary leakage, and lymphatic drainage can be evaluated with methods described in this monograph, the only valid way to evaluate the clinical effect of a drug is with a well-conducted clinical trial that fulfills basic clinical, scientific, and ethical requirements.⁵¹⁶ The trial must be randomized and ideally double-blind with adequate power and should try to answer a well-defined question that corresponds to the disease state. The clinical problem should be classified before and after, with the use of a scoring system such as CEAP.

Symptoms, signs, and quality of life should be evaluated as indicated here at the beginning, during, and at the end of the clinical trial. Hemodynamic evaluation should be performed, preferably with noninvasive techniques that are selected according to which is most likely to provide an answer to the question asked. The specific effects of the drug should be monitored under standardized conditions such as room temperature and time of day. Any unexpected events, both subjective and objective, should be noted and followed up.

Sclerotherapy

There are 2 consensus statements on guidelines for sclerotherapy.^{517–519} Sclerotherapy is effective for some forms of CVI, but it is very difficult to assess results because there are many different techniques. It is desirable to use the CEAP classification to define the precise venous problem. In addition, vein size must be measured so future prospective randomized trials with long-term follow-up can define the proper place of sclerotherapy in relation to clinical outcome. The areas that require controlled trials of sclerotherapy include perforating veins, superficial and residual veins, secondary varicose veins associated with the postthrombotic syndrome, prevention of ulcer recurrence, and some venous dysplasias.

Surgery of the Superficial and Perforating Veins

There are 3 reasons to evaluate the results of surgery. The first is to document long-term clinical improvement in indi-

vidual patients and to establish whether further treatment is required. Second, a fundamental knowledge of the pathophysiology is required to evaluate established and new therapies for research purposes. Third, evaluation is needed to audit and assess cost effectiveness.

Clinical assessment with the CEAP classification may be sufficient for patients treated for isolated superficial vein incompetence. Postoperative investigation may be performed to evaluate completeness of surgical treatment in patients with more advanced CVI. Objective assessment is required for patients who fail to improve, develop recurrent symptoms or signs, or are participating in clinical trials. Duplex scanning is the test of choice to confirm the abolition of superficial or perforator reflux and air-plethysmography or foot volumetry to quantify the hemodynamic changes.

Deep Venous Reconstruction

Improved functional outcome after deep valve reconstruction has been established,^{242,520,521} but this challenging field requires further study and evaluation. A randomized study that compares traditional nonsurgical methods with surgical reconstruction must be performed. Clinical and quality-of-life outcomes should be complemented by appropriate investigations such as duplex scanning and air-plethysmography or foot volumetry, which should provide both anatomic and functional evaluation of the surgical outcome.

Investigation of Congenital Malformations

Congenital vascular malformations are present in a relatively small percentage of patients, but the magnitude and severity of the clinical manifestations can be staggering. The arterial, venous, and lymphatic systems may be involved, either alone or in combination, as in the Parkes-Weber, Maffucci, and Klippel-Trenaunay syndromes. The diagnosis and management of these congenital vascular malformations require a multidisciplinary approach and knowledge of the pathophysiology involved.

The physician must decide how far it is necessary to investigate a patient with a vascular malformation. If the clinical symptoms indicate that something should be done, the first challenge is to decide how to approach the problem. If not, then the instinct to investigate should be replaced by commonsense and consideration for the patient. Well-vascularized tumors may mimic vascular malformations⁵²² and should be distinguished from the latter through biopsy where appropriate.

Diagnostic Process

The diagnostic process begins with a good clinical evaluation. The presence of tissue hypertrophy (gigantism), varicose veins, and a port wine stain suggests a genetic mutation that consists of the Klippel-Trenaunay, Parkes-Weber, and Sturges-Weber syndromes. Genetic investigations are justified only in specific research protocols related to genetics and in centers with the facilities to conduct them. Venous malformations as well as congenital arteriovenous fistulae cause venous hypertension, leading to CVI. Bone and cartilage anomalies are common in the Maffucci syndrome, where the

presence of large hemangiomas and phleboliths makes it necessary to investigate the soft tissues in addition to the skeleton. The clinical examination will determine the system or systems that must be investigated.

Hemodynamic Evaluation

A bidirectional Doppler examination can assess reflux in the superficial venous system, the abnormal vena marginalis of the Klippel-Trenaunay syndrome, and the large perforating veins found in the presence of arteriovenous fistulas. Duplex scanning with color flow imaging detects the sites and extent of reflux, the presence or absence of a deep venous system, and venous aneurysms, which occur in 5% to 20% of patients with congenital venous malformations. Venous occlusion plethysmography can be used to measure increased resting blood flow in patients with arteriovenous fistulas. Plethysmographic methods may document the large venous capacitance typically seen in patients with the Klippel-Trenaunay and Parkes-Weber syndromes. Obstruction of VO due to deep venous atresia of the proximal trunks will also be documented. Readings should be repeated with compression of the entire large lateral collector shortly before the thigh cuff is deflated to assess the importance and contribution of the large vena marginalis in the VO of the limb. Air-plethysmography will quantify reflux in patients with venous insufficiency due to congenital avaluvalia or phlebectasia. Air-plethysmography can document the hemodynamic derangement in the venous circulation and calf muscle pump function. AVP determinations are important to objectively document venous hypertension. This is especially necessary in patients with proximal venous obstruction when bypass procedures are contemplated. In patients with extensive congenital arteriovenous fistulas, cardiac catheterization is sometimes necessary to assess cardiac function and the magnitude of shunting. In such cases, serial arteriography or digital computed arteriography assists in mapping the areas of shunting and their magnitude. A small percentage of Klippel-Trenaunay patients have "hypoactive" arteriovenous shunts that can be detected only with isotopic techniques.^{523,524} Venous occlusion plethysmography as well as the estimation of volume flow in the common femoral veins by duplex scanning can be used to measure increased resting blood flow in patients with arteriovenous fistulas.

Venous Imaging

Ascending and descending phlebography and direct varicography are required in the investigation of venous malformations. Varicography demonstrates the anatomy of the region and locates the point at which the abnormal lateral collector drains into the deep system. Descending phlebography is used to assess reflux and detect the absence of valves; ascending phlebography is used to assess and detect the distribution of the collector systems, perforators, and degree of aplasia or hypoplasia of the deep system. Some patients with the Klippel-Trenaunay syndrome have a large venous capacitance, so ascending phlebography must be performed in 2 phases: the first with the superficial system compressed by elastic bandages and the second without compression. The

deep system is visualized during the first phase. Compression prevents the misinterpretation of deep venous hypoplasia/aplasia by blocking the superficial system and allowing the deep veins to fill preferentially.

Imaging of the Skeleton and Soft Tissues

Both spiral CT and MRI are used to assess the extent of a venous malformation. MRI augments the diagnosis of large vein atresia and shows the localization of abnormal venous collectors and the degree of enlargement of an extremity and clearly displays the distribution of the malformation in the soft tissues.⁵²⁵ Sequences of T2 weighing with second echo-enhanced venous imaging and are useful in demonstrating intrathoracic hemangiomas. T1 sequences show the subcutaneous and intramuscular distribution of a venous malformation. Plain radiographs can be used to evaluate the degree of osteolysis and shortening or enlargement of large bones in some predominantly venous malformations.

Lymphatic Imaging

Lymphoscintigraphy with tagged albumin or ^{99m}Tc-labeled colloids can be used to determine involvement of the lymphatic system in congenital malformations and other lymphatic disorders. Isotope lymphoscintigraphy lacks the anatomic detail of lymphangiography, but it provides specific information about lymph flow and its abnormalities. There may be patterns of delayed transport, skin backflow, or lymphatic disruption.

Hematological Studies

Patients who have CVI as a result of valve destruction that complicates prior venous thrombosis may have an underlying thrombotic risk. This is usually due to activated protein C resistance, but other abnormalities of the coagulation system may also be present. These include protein C, protein S, and antithrombin III deficiency or the presence of lupus anticoagulant. Patients with a family history of CVI and multiple previous spontaneous venous thrombotic episodes or pulmonary embolism should be tested for these conditions.⁵²⁶

Thrombocytopenia and bleeding disorders are often part of the clinical picture in hemangiomatosis (Kasabach-Merritt syndrome), so a complete hematological and fibrinolytic profile is necessary in these cases.

Tissue Biopsy

Malignant degeneration is a potential outcome in large chronic leg ulcers. Biopsy samples obtained from affected areas may be essential for diagnosis. Echondroma and malignant degeneration of hemangiomas are frequent in the Maffucci syndrome.

Appendix

Complete List of Authors

A.N. Nicolaidis (Chairman and IUA representative; UK); L. Abenhaim (Canada); H. Åkeson (Sweden); G.B. Agus (Italy); C. Allegra (Secretary; Italy); G.M. Andreozzi (Italy); P. Balas (Greece); F.

Becker (France); G. Belcaro (Italy); G.G. Belz (Germany); J. Bergan (United States); D. Bergqvist (Sweden); V. Blazek (Germany); H. Boccalon (France); M.R. Boisseau (France); E. Bouskela (Brazil); P. Carpentier (France); L. Castellani (France); D. Christopoulos (Greece); D. Clement (Belgium); P. Coleridge-Smith (UK); A. Cornu-Thenard (France); M.C. Dalsing (United States); A. Davies (UK); M. De Castro Silva (Brazil); K. Delis (UK); T. El-Atrozy (Egypt); B. Eklof (United States); E.A. Enrici (Argentina); K. Esato (Japan); B. Fagrell (Sweden); J. Fareed (United States); J. Fernandes e Fernandes (ESVS representative; Portugal); D. Fitzgerald (Ireland); J. Fletcher (Australia); U. Franzcek (Switzerland); G. Geroulakos (UK); P. Glociczki (United States); M. Griffin (UK); J. Gruss (Germany); R. Greenhalgh (UK); J. Hobbs (CDER Trust representative; UK); U. Hoffmann (Germany); S. Hoshino (Japan); E.A. Hussain (Egypt); V. Ibegbuna (UK); G. Jantet (UIP representative; France); E. Kalodiki (Associate Secretary; UK); L. Killewich (United States); R. Kistner (AVF representative; United States); X. Kurz (Belgium); N. Labropoulos (Associate Secretary; United States); R. Lacour (Argentina); A. Lechter (Colombia); J. Leal-Monedero (Spain); A. Lennox (Australia); L. Levien (South Africa); E.M. Masuda (United States); G. McMullin (Australia); M. Meissner (United States); G. Moneta (United States); K. Myers (Australia); R. Naga (Egypt); P. Neglen (United States); L. Norgren (ESVS representative; Sweden); S. Novo (IASACO representative; Italy); T. O'Donnell (United States); A. O'Shaughnessey (Ireland); H. Patsch (Austria); M.R. Perrin (France); A. Pietravallo (Argentina); R. Poblete Silva (Chile); S. Raju (United States); N. Rich (United States); G. Richardson (Australia); H. Rieger (IUA representative; Germany); C.V. Ruckley (UK); S. Salas Flores (Chile); R. Samson (United States); U. Schultz-Ehrenberg (Germany); A. Scuderi (Brazil); J. Scurr (UIP representative; UK); H. Shigematsu (Japan); R. Simkin (Argentina); S. Simonian (United States); G. Stansby (UK); E. Strandness (United States); A. Strano (IASACO representative; Italy); D. Sumner (United States); J. Struckman (Denmark); G. Szendro (Israel); O. Thulesius (Sweden); J. Ulloa (Colombia); M. Vayssairat (France); M. Vandendreissche (UK); P. Vanhoutte (France); A. Van Rij (New Zealand); M. Veller (South Africa); L. Villavicencio (AVF representative; United States); P. Walker (Australia); L. Willows (UK); Th. Wupperman (Germany); Y. Yasaki (Japan); and P. Zamboni (Italy).

Acknowledgments

This consensus document was supported by educational grants from the Institute de Recherches Internationales Servier and the Cardiovascular Disease Educational and Research Trust (CDERT). The authors are grateful to the members and staff of these societies and organizations for their support that made the development of this document possible. We are also grateful to Anne Taft, Jennifer Sano, Susan Francis, and Elizabeth Thornton for their administrative and secretarial help.

References

1. Abenhaim L, Kurz X, Norgren L, et al. The management of chronic venous disorders of the leg: an evidence-based report of an international task force. *Phlebology*. 1999;14(suppl 1):1-126.
2. Kurz X, Kahn SR, Abenhaim L, et al. Chronic venous disorders of the leg: epidemiology, outcomes, diagnosis and management: summary of an evidence-based report of the VEINES Task Force. *Int Angiol*. 1999; 18:83-102.
3. Weddell JM. Varicose Veins Pilot Study. *Br J Prev Soc Med*. 1966;23: 179-186.
4. Mekky S, Schilling RSF, Walford J. Varicose veins in women cotton workers: an epidemiological study in England and Egypt. *BMJ*. 1969; 2:591-595.
5. Coon MM, Willis PW, Keller JB. Venous thromboembolism and other venous disease in the Tecumseh Community Health Study. *Circulation*. 1973;48:839-846.
6. Guberan W, Widmer LK, Glaus L, et al. Causative factors of varicose veins: myths and facts. *Vasa*. 1973;2:115-120.

7. Da Silva A, Widmer LK, Martin H, et al. Varicose veins and chronic venous insufficiency: prevalence and risk factors in 4376 subjects in the Basle Study II. *Vasa*. 1974;3:118–125.
8. Beaglehole R, Prior IAM, Salmond CE, et al. Varicose veins in the South Pacific. *Int J Epidemiol*. 1975;4:295–299.
9. Widmer LK. *Peripheral Venous Disorders: Prevalence and Socio-Medical Importance: Observations in 4529 Apparently Healthy Persons: Basle III Study*. Bern, Switzerland: Hans Huber; 1978:1–90.
10. Abramson JH, Hopp C, Epstein LM. The epidemiology of varicose veins: a survey of Western Jerusalem. *J Epidemiol Commun Health*. 1981;35:213–217.
11. Strano A, Novo S, Avellone G, et al. Prévalence des varices primitives des membres inférieurs dans une population randomisée de la Sicile occidentale. *Art Veines*. 1984;2:167–171.
12. Novo S, Avellone G, Pinto A, et al. Prevalence of primitive varicose veins of lower limbs in a random population sample of western Sicily. *Int Angiol*. 1988;7:176–181.
13. Stvrtinova V, Kolesar J, Wimmer G. Prevalence of varicose veins of the lower limbs in the women working at a department store. *Int Angiol*. 1991;10:2–5.
14. Brand FN, Dannenberg AL, Abbott RD, et al. The epidemiology of varicose veins: the Framingham study. *Am J Prev Med*. 1988;4:96–101.
15. Callam MJ, Ruckley CV, Harper DR, et al. Chronic ulceration of the leg: extent of the problem and provision of care. *BMJ*. 1985;290:1855–1856.
16. Cornwall JV, Doré CJ, Lewis JD. Leg ulcers: epidemiology and aetiology. *Br J Surg*. 1986;73:693–696.
17. Henry M. Incidence of varicose ulcers in Ireland. *Ir Med J*. 1986;79:65–67.
18. Baker SR, Stacey, C, Koll-McKay AG, et al. Epidemiology of chronic venous ulcers. *Br J Surg*. 1991;78:864–867.
19. Nelzen O, Bergqvist D, Lindhagen A, et al. Chronic leg ulcers: an underestimated problem in the primary health care among elderly patients. *J Epidemiol Commun Health*. 1991;45:184–187.
20. Lindholm C, Bjellerup M, Christensen OB, et al. A demographic survey of leg and foot ulcer patients in a defined population. *Acta Derm Venereol*. 1992;72:227–230.
21. Lees TA, Lambert D. Prevalence of lower limb ulceration in an urban health district. *Br J Surg*. 1992;79:1032–1034.
22. Andersson E, Hansson C, Swanbeck G. Leg and foot ulcer prevalence and investigation of the peripheral arterial and venous circulation in a randomised elderly population: an epidemiological survey and clinical investigation. *Acta Derm Venereol*. 1993;73:57–61.
23. Nelzen O, Bergqvist D, Lindhagen A. Leg ulcer etiology: a cross sectional population study. *J Vasc Surg*. 1991;14:557–564.
24. Wille-Jorgensen P, Jorgensen T, Andersen M, et al. Postphlebotic syndrome and general surgery: an epidemiologic investigation. *Angiology*. 1991;42:397–403.
25. Franks PJ, Wright DD, Moffatt CJ, et al. Prevalence of venous disease: a community study in west London. *Eur J Surg*. 1992;158:143–147.
26. Skene AI, Smith JM, Doré CJ, et al. Venous leg ulcers: a prognostic index to predict time to healing. *BMJ*. 1992;305:1119–1121.
27. Callam MJ, Harper DR, Dale JJ, et al. Chronic ulcer of the leg: clinical history. *BMJ*. 1987;294:1389–1391.
28. Hanson C, Andersson E, Swanbeck G. A follow-up study of leg and foot ulcer patients. *Acta Derm Venereol*. 1987;67:496–500.
29. Mayberry JC, Moneta GL, De Frang RD, et al. The influence of elastic compression stockings on deep venous haemodynamics. *J Vasc Surg*. 1991;13:91–100.
30. Dinn E, Henry M. Treatment of venous ulceration by injection sclerotherapy and compression hosiery: a 5 year study. *Phlebology*. 1992;7:23–26.
31. Da Silva A, Navarro MF, Batalheiro J. The importance of chronic venous insufficiency: various preliminary data on its medico-social consequences. *Phlebologie*. 1992;45:439–443.
32. De Castro-Silva M. Chronic venous insufficiency of the lower limbs and its socioeconomic significance. *Int Angiol*. 1991;10:152–157.
33. Callam M. Prevalence of chronic leg ulceration and severe chronic venous disease in Western Countries. *Phlebology*. 1992;7(suppl 1):6s–12s.
34. Jantet G. Impact socio-économique de la pathologie veineuse en Grande Bretagne. *Phlebologie*. 1992;45:433–437.
35. Hume M. Presidential address: a venous renaissance? *J Vasc Surg*. 1992;15:947–951.
36. Laing W. *Chronic Venous Diseases of the Leg*. London, UK: Office of Health Economics; 1992:1–44.
37. Lafuma A, Fagnani F, Peltier-Pujol F, et al. La maladie veineuse en France: un problème de santé publique méconnu. *J Mal Vasc*. 1994;19:185–189.
38. Zsoter T, Cronin RF. Venous distensibility in patients with varicose veins. *Can Med Assoc J*. 1966;94:1293–1297.
39. Lechter A, Alvarez A, López G. Pelvic varices and gonadal veins. *Phlebology*. 1987;2:181–188.
40. Gupta A, McCarthy S. Pelvic varices as a cause for pelvic pain: MRI appearance. *Magn Reson Imaging*. 1994;12:679–681.
41. Periset A, Ley J, Carderón J, et al. Clínica angiologica. In: Leal J, ed. *Insuficiencia Venosa Crónica de la Pelvis y de los Miembros Inferiores*. Madrid, Spain: Mosby/Doyma Libros SA; 1997:43–52.
42. Shepherd JT, Vanhoute PM. *Veins and Their Control*. Philadelphia, Pa: WB Saunders; 1975.
43. Shepherd JT, Vanhoute PM. *The Human Cardiovascular System: Facts and Concepts*. New York, NY: Raven Press; 1979.
44. Bollinger A, Leu AJ, Hoffmann U, et al. Microvascular changes in venous disease: an update. *Angiology*. 1997;48:27–32.
45. Plate G, Brudin L, Eklof B, et al. Congenital vein valve aplasia. *World J Surg*. 1986;10:929–934.
46. Morano JU, Raju S. Chronic venous insufficiency: assessment with descending phlebography. *Radiology*. 1990;174:441–444.
47. Shami SK, Sarin S, Cheatle TR, et al. Venous ulcers and the superficial venous system. *J Vasc Surg*. 1993;17:487–490.
48. Gullmo A. The strain obstruction syndrome of the femoral vein. *Acta Radiol Scand*. 1957;47:119–137.
49. Browse NL, Burnand KG, Thomas ML. *Diseases of the Veins. Pathology, Diagnosis and Treatment*. London, UK: Hodder and Stoughton; 1988.
50. Gloviczki P, Stanton AW, Sticker GB, et al. Klippel-Trenaunay syndrome: the risks and benefits of vascular interventions. *Surgery*. 1991;110:469–479.
51. Ferrari E Jr. Un'interessante alterazione della vena iliaca comune di sinistra al suo sbocco nella vena cava inferiore: suoi rapporti con la trombosi. *Arch Ital Anat Istol Patol*. 1940;12:239–293.
52. May R, Thurner J. Ein Gefässporen in der V. iliaca comm. sin als wahrscheinliche Ursache der uberwiegend linksseitigen Beckenvenenthrombose. *Z Kreislaufforsch*. 1956;45:912–917.
53. May R, Thurner J. The cause of predominantly sinistral occurrence of thrombosis in the pelvic veins. *Angiology*. 1957;8:419–427.
54. Cockett FB, Thomas ML. The iliac compression syndrome. *Br J Surg*. 1965;52:816–821.
55. Rich NM, Hughes CW, Baugh JH. Management of venous injuries. *Ann Surg*. 1970;171:724–730.
56. Rich NM, Hobson RW, Collins GJ, et al. The effect of acute popliteal venous interruption. *Ann Surg*. 1976;183:365–368.
57. Willén J, Bergqvist D, Hallböök T. Venous insufficiency as a late complication after tibial fracture. *Acta Orthop Scand*. 1982;53:149–153.
58. Rich NM. Principles and indications for primary venous repair. *Surgery*. 1982;91:492–496.
59. Lindhagen A, Bergqvist D, Hallböök T, et al. Venous function after fracture of the lower extremity: a 9-year follow up of 150 cases. *Acta Orthop Scand*. 1985;56:110–114.
60. Dajani OM, Haddad F, Hajj HA, et al. Injury to the femoral vessels: the Lebanese war experience. *Eur J Vasc Surg*. 1988;2:293–296.
61. Aitken RJ, Matley PJ, Immelman EJ. Lower limb vein trauma: a long term clinical and physiological assessment. *Br J Surg*. 1989;76:585–588.
62. Olivier C. Le rétablissement de la circulation apres phlébite du membre inférieur. *Presse Med*. 1945;32:433–434.
63. Linton R, Hardy I. Post-thrombotic syndrome of the lower extremity: treatment by interruption of the superficial femoral vein and ligation and stripping of the short and long saphenous veins. *Surgery*. 1948;24:452–468.
64. May R, Nissl R. The relevance of phlebography in the diagnostics and treatment of deep phlebothromboses of the leg. *Munch Med Wochr*. 1973;115:2182–2188.
65. Langeron P. Classification generale des syndromes post-phlébitiques et indications thérapeutiques. *Phlebologie*. 1974;27:463–467.
66. Killewich LA, Bedford GR, Beach KW, et al. Spontaneous lysis of deep venous thrombi: rate and outcome. *J Vasc Surg*. 1989;9:89–97.
67. Markel A, Manzo RA, Bergelin RO, et al. Valvular reflux after deep vein thrombosis: incidence and time of occurrence. *J Vasc Surg*. 1992;15:377–384.

68. O'Shaughnessy AM, FitzGerald DE. Organisation patterns of venous thrombus over time as demonstrated by duplex ultrasound. *J Vasc Invest*. 1996;2:75–81.
69. O'Shaughnessy AM, FitzGerald DE. Natural history of proximal deep vein thrombosis assessed by duplex ultrasound. *Int Angiol*. 1997;16:45–49.
70. Kakkar VV, Lawrence D. Hemodynamic and clinical assessment after therapy for acute deep vein thrombosis: a prospective study. *Am J Surg*. 1985;150:54–63.
71. Killewich LA, Martin R, Cramer M, et al. An objective assessment of the physiologic changes in the post-thrombotic syndrome. *Arch Surg*. 1985;120:424–426.
72. Lindner DJ, Edwards JM, Phinney ES, et al. Long-term hemodynamic and clinical sequelae of lower extremity deep vein thrombosis. *J Vasc Surg*. 1986;4:436–442.
73. Saarinen J, Sisto T, Laurikka J, et al. Late sequelae of acute deep venous thrombosis: evaluation five and ten years after. *Phlebology*. 1995;10:106–109.
74. O'Donnell TF, Browse NL, Burnand KG, et al. The socioeconomic effects of an iliofemoral venous thrombosis. *J Surg Res*. 1977;22:483–488.
75. Strandness DEJ, Langlois Y, Cramer M, et al. Long-term sequelae of acute venous thrombosis. *JAMA*. 1983;250:1289–1292.
76. Lindhagen A, Bergqvist A, Bergqvist D, et al. Late venous function in the leg after deep venous thrombosis occurring in relation to pregnancy. *Br J Obstet Gynaecol*. 1986;93:1289–1290.
77. Norris CS, Darrow JM. Hemodynamic indicators of post-thrombotic sequelae. *Arch Surg*. 1986;121:765–768.
78. Åkesson H, Bundin L, Dahlstrom JA, et al. Venous function assessed during a 5 year period after acute iliofemoral venous thrombosis treated with anticoagulation. *Eur J Vasc Surg*. 1990;4:43–48.
79. Bergqvist D. Prophylaxis against postoperative venous thromboembolism: a survey of surveys. *Thromb Haemorrh Disord*. 1990;2:69–73.
80. Heldal M, Seem E, Sandset PM, et al. Deep vein thrombosis: a 7-year follow-up study. *J Intern Med*. 1993;234:71–75.
81. Milne AA, Ruckley CV. The clinical course of patients following extensive deep vein thrombosis. *Eur J Vasc Surg*. 1994;8:56–59.
82. Milne AA, Stonebridge PA, Bradbury AW, et al. Venous function and clinical outcome following deep vein thrombosis. *Br J Surg*. 1994;81:847–849.
83. van Ramshorst B, van Bemmelen PS, Hoenvelde H, et al. The development of valvular incompetence after deep vein thrombosis: a follow-up study with duplex scanning. *J Vasc Surg*. 1994;20:1059–1066.
84. van Haarst EP, Liasis N, van Ramshorst B, et al. The development of valvular incompetence after deep vein thrombosis: a 7 year follow-up study with duplex scanning. *Eur J Vasc Endovasc Surg*. 1996;12:295–299.
85. Labropoulos N, Leon M, Nicolaidis AN, et al. Venous reflux in patients with previous deep venous thrombosis: correlation with ulceration and other symptoms. *J Vasc Surg*. 1994;20:20–26.
86. Johnson BF, Manzo RA, Bergelin RO, et al. Relationship between changes in the deep venous system and the development of the post-thrombotic syndrome after an acute episode of lower limb deep vein thrombosis: a one- to six-year follow-up. *J Vasc Surg*. 1995;25:307–313.
87. Prandoni P, Lensing AWA, Cogo A, et al. The long-term clinical course of acute deep venous thrombosis. *Ann Intern Med*. 1996;125:1–7.
88. Franzeck UK, Schach I, Jager KA, et al. Prospective 12-year follow-up study of clinical and hemodynamic sequelae after deep vein thrombosis in low-risk patients (Zurich Study). *Circulation*. 1996;93:74–79.
89. Brandjes DPM, Büller H, Heijboer H, et al. Randomised trial of effect of compression stockings in patients with symptomatic proximal-vein thrombosis. *Lancet*. 1997;349:759–762.
90. Sindrup JH, Avnstorp C, Steenfors HH, et al. Transcutaneous PO₂ and laser Doppler blood flow measurements in 40 patients with venous leg ulcers. *Acta Derm Venereol*. 1987;67:160–182.
91. Belcaro G, Grigg M, Rulo A, et al. Blood flow in the perimalleolar skin in relation to posture in patients with venous hypertension. *Ann Vasc Surg*. 1989;3:5–7.
92. Franzeck U, Bollinger A, Huch R, et al. Transcutaneous oxygen tension and capillary morphological characteristics and density in patients with chronic venous incompetence. *Circulation*. 1984;70:806–811.
93. Allegra C. Relationship between relative haematocrit and blood cell velocity in human skin capillaries in chronic venous insufficiency. *Int J Microcirc Clin Exp*. 1994;14(suppl 1):52.
94. Bollinger A, Fagrell B. *Clinical Capillaroscopy: A Guide to Its Use in Clinical Research and Practice*. Bern, Switzerland: Hogrefe & Huber Publishers; 1990.
95. Bollinger A, Jaeger K, Sgier F, et al. Fluorescence microlymphography. *Circulation*. 1981;64:1195–1200.
96. Fagrell B. Local microcirculation in chronic venous incompetence and leg ulcers. *Vasc Surg*. 1979;13:217–225.
97. Fagrell B. Microcirculatory disturbances: the final cause for venous leg ulcers? *Vasa*. 1982;11:101–103.
98. Belcaro G, Laurora G, Cesarone MR, et al. Microcirculation in high perfusion microangiopathy. *J Cardiovasc Surg*. 1995;36:393–398.
99. Leu AJ, Yanar A, Pfister G, et al. Mikroangiopathie bei chronischer venöser Insuffizienz. *Dtsch Med Wochenschr*. 1991;116:447–453.
100. Leu AJ, Franzeck UK, Bollinger A. Microangiopathies in chronic venous insufficiency. *Ther Umsch*. 1991;48:715–721.
101. Leu AJ, Leu HJ, Franzeck UK, et al. Microvascular changes in chronic venous insufficiency: a review. *Cardiovasc Surg*. 1995;3:237–245.
102. Shami SK, Chittenden SJ, Scurr JH, et al. Skin blood flow in chronic venous insufficiency. *Phlebology*. 1993;8:72–76.
103. Bollinger A, Leu AJ. Evidence for microvascular thrombosis obtained by intravital fluorescence videomicroscopy. *Vasa*. 1991;3:252–255.
104. Browse NL, Burnand KG. The cause of venous ulceration. *Lancet*. 1982;2:243–245.
105. Bollinger A, Isenring G, Franzeck UK. Lymphatic microangiopathy: a complication of severe chronic venous incompetence (CVI). *Lymphology*. 1982;15:60–65.
106. Leu AJ, Hoffmann U. Initial lymphatics of the skin: from basic research to clinical implications. *J Vasc Invest*. 1997;3:143–148.
107. Thomas PRS, Nash GB, Dormandy JA. White cell accumulation in the dependent legs of patients with venous hypertension: a possible mechanism for trophic changes in the skin. *BMJ*. 1988;296:1693–1695.
108. Vanscheidt W, Kresse OH, Hach-Wunderle V, et al. Leg ulcer patient: no decreased fibrinolytic response but white cell trapping after venous occlusion of the upper limb. *Phlebology*. 1993;8:151–154.
109. Whinston RJ, Hallett MB, Lane LF, et al. Lower limb neutrophil oxygen radical production is increased in venous hypertension. *Phlebology*. 1993;8:151–154.
110. Schields DA, Andaz SK, Abeysinghe RD, et al. Plasma lactoferrin as a marker of white cell degranulation in venous disease. *Phlebology*. 1994;9:55–58.
111. Veraart JC, Verhaegh ME, Neumann HA, et al. Adhesion molecule expression in venous leg ulcers. *Vasa*. 1993;22:213–218.
112. Schields DA, Andaz SK, Timothy-Antoine CA, et al. CD11b/CD18 as a marker of neutrophil adhesion in experimental ambulatory venous hypertension. *Phlebology*. 1995;10(suppl 1):220–221.
113. Coleridge-Smith PD, Thomas P, Scurr JH, et al. Causes of venous ulceration: a new hypothesis. *BMJ*. 1988;296:1693–1695.
114. Le Dévéhat C, Boisseau MR, Vimeux M, et al. Hemorheological factors in the pathophysiology of venous disease. *Clin Hemorheol*. 1989;9:861–870.
115. Boisseau MR, Roudaut MF, Seigneur M, et al. Relationship between age, fibrinogen and clinical status in 313 patients with CVI. *Bio-rheology*. 1995;32:279.
116. Falanga V, Kruskal J, Franks JJ. Fibrin- and fibrinogen-related antigens in patients with venous disease and venous ulceration. *Arch Dermatol*. 1991;127:75–78.
117. Leach RD. Venous ulceration, fibrinogen and fibrinolysis. *Ann R Coll Surg Engl*. 1984;66:258–263.
118. Dormandy JA, Nash A. Importance of red cell aggregation in venous pathology. *Clin Hemorheol*. 1987;7:119–122.
119. Boisseau MR, Freyburger G, Busquet M, et al. Hemorheological disturbances in venous insufficiency after induced stasis. *Clin Hemorheol*. 1989;9:161–163.
120. Ernst E, Matrai A, Marshall M. Limited blood fluidity as a contributory factor of venous stasis in chronic venous insufficiency. *Phlebology*. 1989;4:107–111.
121. Wolfe JHN, Morland M, Browse NL. The fibrinolytic activity of varicose veins. *Br J Surg*. 1979;66:185–187.
122. Hach V, Fink M, Bles N, et al. Tissue fibrinolytic activity in different types of varicose veins. *Angiology*. 1986;37:718–724.
123. Browse NL, Gray L, Jarret PEM, et al. Blood and vein wall fibrinolytic activity in health and vascular disease. *BMJ*. 1977;1:478–481.
124. Gajraj H, Browse NL. Fibrinolytic activity and calf pump failure. *Br J Surg*. 1991;78:1009–1012.

125. Gajraj H, Browse NL. Fibrinolytic activity of the arms and legs of patients with lower limb venous disease. *Br J Surg*. 1991;78:853–856.
126. Ibbotson SH, Layton AM, Davies JA, et al. Plasminogen activator inhibitor (PAI-1) levels in patients with chronic venous leg ulcerations. *Br J Dermatol*. 1994;131:738. Letter.
127. Boisseau MR, Taccoen A, Garreau C, et al. Fibrinolysis and haemoreology in chronic venous insufficiency: a double blind study of troxerutin efficiency. *J Cardiovasc Surg*. 1995;36:369–374.
128. Margolis DJ, Kruihof EK, Barnard M, et al. Fibrinolytic abnormalities in two different cutaneous manifestations of venous disease. *J Am Acad Dermatol*. 1996;34:204–208.
129. Prins MM, Hirsh J. A critical review of the evidence supporting a relationship between impaired fibrinolytic activity and venous thromboembolism. *Arch Intern Med*. 1991;151:1721–1731.
130. Kaiser B, Hoppensteadt DA, Fareed J. Recombinant TFPI and variants: potential implications in the treatment of cardiovascular disorders. *Exp Opin Invest Drugs*. 1998;7:1–30.
131. Gourdin FW, Smith JG Jr. Etiology of venous ulceration. *South Med J*. 1993;86:1142–1146.
132. Zuccarelli F, Taccoen A, Razavian M, et al. Increasing erythrocyte aggregability with the progressive grades of chronic venous insufficiency: importance and mechanisms. *J Cardiovasc Surg*. 1995;36:387–391.
133. Wilkinson LS, Bunker C, Edwards JC, et al. Leukocytes: their role in the etiopathogenesis of skin damage in venous disease. *J Vasc Surg*. 1993;17:669–675.
134. Becker F. Mechanisms, epidemiology and clinical evaluation of venous insufficiency of the lower limbs. *Rev Prat*. 1994;44:726–731.
135. Becker F, Menassa M, Gabrielle F, et al. What complementary examinations to demand in chronic venous insufficiency? *Phlebologie*. 1992;45:297–303.
136. Christopoulos DG, Nicolaides AN, Szendro G, et al. Air-plethysmography and the effect of elastic compression on venous hemodynamics of the leg. *J Vasc Surg*. 1987;5:148–59.
137. Nicolaides AN, Kakkar VV, Field ES, et al. The origin of deep vein thrombosis: a venographic study. *Br J Radiol*. 1971;44:653–663.
138. May R, Nissl R. *Die Phlebographie der unteren Extremität*. Stuttgart, Germany: Thieme Stuttgart; 1973.
139. Lea Thomas M. *Phlebography of the Lower Limb*. Edinburgh, UK, Churchill Livingstone; 1982.
140. Hach W. Varicose veins of the deep perforating veins: a typical phlebologic disease picture. *Vasa*. 1985;14:155–157.
141. Zubicoa S, Carrion O, Ley J, et al. Métodos invasivos en el diagnóstico de la insuficiencia venosa crónica: radiología pélvica y de miembros inferiores. In: Leal J, ed. *Insuficiencia Venosa Crónica de la Pelvis y de los Miembros Inferiores*. Madrid, Spain: Mosby/Doyma Libros SA; 1997:75–88.
142. DeWeese JA, Roggof SM. Phlebographic patterns in acute deep venous thrombosis of the leg. *Surgery*. 1963;53:99–108.
143. Raju S, Fredericks R. Venous obstruction: an analysis of one hundred thirty-seven cases with hemodynamic, venographic and clinical correlations. *J Vasc Surg*. 1991;14:305–313.
144. Kistner RL, Kamida CB. Update on phlebography and varicography. *Dermatol Surg*. 1995;21:71–76.
145. Perrin M, Bolot JE, Genevois A, et al. Dynamic popliteal phlebography. *Phlebologie*. 1988;41:429–440.
146. Cid dos Santos J. Sur quelques vérités premières oubliées ou méconnues de l'anatomie-physiologie normale et pathologique du système veineux. *Amatus Lusiramis*. 1948;7:5–32.
147. Luke JC. The deep vein valves: a venographic study in normal and postphlebotic states. *Surgery*. 1951;29:381–386.
148. Gullmo A. On the technique of phlebography of the lower limb. *Acta Radiol*. 1956;46:601–620.
149. Coito A. *Funcão Valvular ne Patologia Venosa*. Lisboa, Portugal: Tese de Doutoramento; 1957.
150. Nylander G. Lower leg phlebography by an improved technique. *Acta Radiol*. 1962;57:348–352.
151. Herman RJ, Neiman HL, Yao JST, et al. Descending venography: a method of evaluating lower extremity valvular function. *Radiology*. 1980;137:63–69.
152. Taheri SA, Sheehan F, Elias S. Descending venography. *Angiology*. 1983;34:299–305.
153. Ackroyd JS, Thomas LM, Browse NL. Deep vein reflux: an assessment by descending phlebography. *Br J Surg*. 1986;73:31–33.
154. Kistner RL, Ferris EB, Randhawa G, et al. A method of performing descending venography. *J Vasc Surg*. 1986;4:464–468.
155. Stacey MC, Burnand KG, Thomas LM, et al. Influence of phlebographic abnormalities on the natural history of venous ulceration. *Br J Surg*. 1991;78:868–871.
156. Marques JS. Valeur de la stereo-phlebographie dans le diagnostic et dans la thérapeutique des maladies veineuses des membres inférieurs. *Phlebologie*. 1973;25:173–190.
157. Perrin M. Phlébographie poplitée dynamique. *Phlébol Ann Vasc*. 1997; suppl:542–546.
158. Gillot C. Phlébographie peropératoire. *Phlébol Ann Vasc*. 1997; suppl:546–551.
159. Stonebridge PA, Chalmers N, Beggs I, et al. Recurrent varicose veins: a varicographic analysis leading to a new practical classification. *Br J Surg*. 1995;82:60–62.
160. Hobbs JT. Peroperative venography to ensure accurate saphenopopliteal ligation. *BMJ*. 1980;280:1578–1579.
161. Hobbs JT. Errors in the differential diagnosis of incompetence of the popliteal vein and the short saphenous vein by Doppler ultrasound. *J Cardiovasc Surg*. 1986;27:169–173.
162. Thomas ML, Bowles JN. Incompetent perforating veins: comparison of varicography and ascending phlebography. *Radiology*. 1985;154:619–623.
163. Hobbs JT. The pelvic congestion syndrome. *Br J Hosp Med*. 1990;43:200–202.
164. Kauppila A. Uterine phlebography with venous compression. *Acta Obstet Gynecol Scand (Suppl)*. 1970;3:1–66.
165. Baux R. Intérêt général de la phlébographie utérine. *Rev Franc Gyn Obstét*. 1982;77:487–494.
166. Leclercq E. Phlebographie intrautérine: hystérogaphic vein and use: University of Liege. *Gynecol Obstet*. 1982;77:491–496.
167. Kennedy A, Hemingway A. Radiology of ovarian varices. *Br J Hosp Med*. 1990;44:38–43.
168. Richardson G, Beckwith T, Sheldon M. Ultrasound windows to abdominal and pelvic veins. *Phlebologie*. 1991;6:111–125.
169. Cranley JJ. *Vascular Surgery: Vol II. Peripheral Venous Diseases*. New York, NY: Harper & Row Publishers Ltd; 1975:70–71.
170. Katayama H, Yamaguchi K, Kozuka T, et al. Adverse reactions to ionic and nonionic contrast media. *Radiology*. 1990;175:621–628.
171. Talbot S. Use of real time imaging in identifying deep venous obstruction: a preliminary report. *Bruit*. 1982;6:41–45.
172. Sullivan ED, Peter DJ, Cranley JJ. Realtime B-mode venous ultrasound. *J Vasc Surg*. 1984;1:465–471.
173. Hannan LJ, Stedje KJ, Skorez MJ, et al. Venous imaging of the extremities: our twenty-five hundred cases. *Bruit*. 1986;10:29–32.
174. Kalodiki E, Marston R, Volteas N, et al. The combination of liquid crystal thermography and duplex scanning in the diagnosis of deep vein thrombosis. *Eur J Vasc Surg*. 1992;6:311–316.
175. Szendro G, Nicolaides AN, Zukowski AJ, et al. Duplex scanning in the assessment of deep venous incompetence. *J Vasc Surg*. 1986;4:237–242.
176. Rollins DL, Semrow C, Friendell ML, et al. The use of ultrasonic venography in the evaluation of venous valve function. *Am J Surg*. 1987;154:189–191.
177. Kalodiki E, Calahoras L, Nicolaides AN. Make it easy: duplex examination of the venous system. *Phlebologie*. 1993;8:17–21.
178. Masuda EM, Kistner RL, Eklof B. Prospective study of duplex scanning for venous reflux: comparison of Valsalva and pneumatic cuff techniques in the reverse Trendelenburg and standing positions. *J Vasc Surg*. 1994;20:711–720.
179. Wolverson MK, Nouri S, Joist JH, et al. The direct visualization of blood flow by realtime ultrasound: clinical observations and underlying mechanisms. *Radiology*. 1981;140:443–448.
180. Sigel B, Machi J, Beitler JC, et al. Variable ultrasound echogenicity in flowing blood. *Science*. 1982;218:1321–1323.
181. Sigel B, Machi P, Beitler J, et al. Red cell aggregation as a cause of blood flow echogenicity. *Radiology*. 1983;148:779–802.
182. Van Bemmelen PS, Bedford G, Beach K, et al. Quantitative segmental evaluation of venous valvular reflux with duplex ultrasound. *J Vasc Surg*. 1989;10:425–431.
183. Sarin S, Sommerville K, Farrar J, et al. Duplex ultrasonography for assessment of venous valvular function of the lower limb. *Br J Surg*. 1994;81:159–165.
184. Lagattolla NRF, Donald A, Lockhart S, et al. Retrograde flow in the deep veins of subjects with normal venous function. *Br J Surg*. 1997;84:36–39.

185. Vasdekis SN, Clarke GH, Hobbs JT, et al. Evaluation of non-invasive and invasive methods in the assessment of short saphenous vein termination. *Br J Surg*. 1989;76:929–932.
186. Engel AF, Davies G, Keeman JN. Preoperative localisation of the saphenopopliteal junction with duplex scanning. *Eur J Vasc Surg*. 1991; 5:507–509.
187. McMullin GM, Coleridge-Smith PD. An evaluation of Doppler ultrasound and photoplethysmography in the investigation of venous insufficiency. *Aust NZ J Surg*. 1992;62:270–275.
188. Sarin S, Scurr JH, Coleridge Smith PD. Medial calf perforators in venous disease: the significance of outward flow. *J Vasc Surg*. 1992; 16:40–46.
189. Jamieson WG. State of art of venous investigation and treatment. *Can J Surg*. 1993;36:119–128.
190. Ruckley CV, Makdooi KR. The venous perforator. *Br J Surg*. 1996; 83:1492–1493.
191. Schutheiss R, Billeter M, Bollinger A, et al. Comparison between clinical examination, CW-Doppler ultrasound and color-duplex sonography in the diagnosis of incompetent perforating veins. *Eur J Endovasc Surg*. 1997;13:122–126.
192. Franco G. Doppler pulsed and color echography of the inferior vena cava. *Phlebologie*. 1993;46:389–392.
193. Messina LM, Sapra MS, Smith MA, et al. Clinical significance of routine imaging of iliac and calf veins by colour flow duplex scanning in patients suspected of having lower extremity deep venous thrombosis. *Surgery*. 1993;114:921–927.
194. Dupas B, el Kouri D, Curdet C, et al. Angiomagnetic resonance imaging of iliofemorocaval venous thrombosis. *Lancet*. 1995;346:17–19.
195. Meissner MH, Manzo RA, Bergelin RO, et al. Deep venous insufficiency: the relationship between lysis and subsequent reflux. *J Vasc Surg*. 1993;18:596–605.
196. Meissner MH, Caps MT, Bergelin RO, et al. Propagation, rethrombosis and new thrombus formation after acute deep venous thrombosis. *J Vasc Surg*. 1995;22:558–567.
197. Labropoulos N, Leon M, Nicolaides AN, et al. Superficial venous insufficiency: correlation of anatomic extent of reflux with clinical symptoms and signs. *J Vasc Surg*. 1994;20:953–958.
198. Labropoulos N, Delis K, Nicolaides AN, et al. The role of the distribution and anatomic extent of reflux in the development of signs and symptoms in chronic venous insufficiency. *J Vasc Surg*. 1996;23: 504–510.
199. Weingarten MS, Branas CC, Czeredarczuk M, et al. Distribution and quantification of venous reflux in lower extremity chronic venous stasis disease with duplex scanning. *J Vasc Surg*. 1993;18:753–759.
200. Hanrahan LM, Araki CT, Rodriguez AA, et al. Distribution of valvular incompetence in patients with venous stasis ulceration. *J Vasc Surg*. 1991;13:805–812.
201. Lees TA, Lambert D. Patterns of venous reflux in limbs with skin changes associated with chronic venous insufficiency. *Br J Surg*. 1993; 80:725–728.
202. Myers KA, Ziegenbein RW, Zeng GH, et al. Duplex ultrasonography scanning for chronic venous disease: patterns of venous reflux. *J Vasc Surg*. 1995;21:605–612.
203. Labropoulos NL, Giannoukas AD, Nicolaides AN, et al. The role of venous reflux and calf muscle pump function in nonthrombotic chronic venous insufficiency. *Arch Surg*. 1996;131:403–406.
204. Dodd H. Varicosity of the external and pseudo-varicosity of the short (external) saphenous vein. *Br J Surg*. 1959;46:520–530.
205. Dodd H. The varicose tributaries of the popliteal vein. *Br J Surg*. 1965;52:350–354.
206. Hobbs JT. The enigma of the gastrocnemius vein. *Phlebology*. 1988;3: 19–30.
207. Thiery L. La vena fossa poplitea. *Phlebologie*. 1983;2:659–661.
208. Vandendriessche M. Association between gastrocnemial vein insufficiency and varicose veins. *Phlebology*. 1989;4:171–184.
209. Hobbs JT. A new approach to short saphenous vein varicosities. In: Bergan JJ, Yao JST, eds. *Surgery of the Veins*. Orlando, Fla: Grune & Stratton; 1985:301–321.
210. Thiery L. A propos du traitement chirurgical de l'insuffisance des veines jumelles. *Phlebologie*. 1991;44:833–836.
211. Claeys R, Thiery L, Uytterhaegen P. La pompe musculaire du mollet: videophlebographie et EMG shutanee. *Phlebologie*. 1993;46:287–292.
212. Rosenberg N, Marchese FP. Perforator vein localisation by heat emission detection. *Surgery*. 1963;53:575–578.
213. Beesley WH, Fegan WG. An investigation into the localisation of incompetent perforating veins. *Br J Surg*. 1970;57:30–32.
214. Patil KD, Williams JR, Lloyd Williams K. Thermographic localisation of incompetent perforating veins in the leg. *BMJ*. 1970;1:195–197.
215. Noble J, Gunn AA. Varicose veins: comparative study of methods for detecting incompetent perforators. *Lancet*. 1972;4:1253–1255.
216. Elem B, Shorey BA, Lloyd Williams K. Comparison between thermography and fluorescein test in the detection of incompetent perforating veins. *BMJ*. 1971;4:651–652.
217. Wojciechowski J, Holm J, Zachrisson. Thermography and phlebography in the detection of incompetent perforating veins. *Acta Radiol Diagn*. 1982;23:199–201.
218. Kalodiki E, Calahoras L, Geroulakos G, et al. Liquid crystal thermography and duplex in the preoperative marking of varicose veins. *Phlebology*. 1995;10:110–114.
219. Pollack AA, Wood EH. Venous pressure in the saphenous vein in ankle in man during exercise and changes in posture. *J Appl Physiol*. 1949;1: 649–662.
220. Arnoldi C. The venous return from the lower leg: a synthesis. *Acta Orthop Scand*. 1964;64(suppl):1–75.
221. Hojensgard IC, Sturup H. On the function of the venous pump and the venous return from the lower limbs. *Acta Dermatol Venereol*. 1952; 32(suppl 29):169–176.
222. Bjordal RI. Pressure patterns in the saphenous system in patients with venous ulcers. *Acta Chir Scand*. 1971;137:495–501.
223. Bauer G. Pathophysiology and treatment of the lower leg stasis syndrome. *Angiology*. 1950;1:1–8.
224. Birger I. The chronic (second) stage of thrombosis in the lower extremities. *Acta Chir Scand*. 1947;129(suppl):1–110.
225. Kuiper JP. Venous pressure determination (direct method). *Dermatologica*. 1964;132:206–217.
226. Nachbur B. Die periphere Venendruckmessung. *Zentralbl Phlebol*. 1971;10:224–230.
227. Kriessmann A. Periphere phlebdynamometrie. *Vasa*. 1975;suppl 4:1–35.
228. Partsch H. Simultane Venendruckmessung und Plethysmographie am Fuss. In: May R, Kriessmann A, eds. *Periphere Venendruckmessung*. Stuttgart, Germany: Georg Thieme Verlag; 1978:147–156.
229. De Marees H, Wuppermann T, Zschege C. Functional testing of the peripheral venous system by means of peripheral circulatory measurements. *Vasa*. 1978;7:282–290.
230. Nicolaides AN, Zukowski AJ. The value of dynamic venous pressure measurements. *World J Surg*. 1986;10:919–924.
231. Strandén E, Ögredt T, Seem E. Venous pressure gradients in controls and in patients with chronic venous disease. *Phlebology*. 1986;1:47–50.
232. Raju S, Fredericks R. Hemodynamic basis of stasis ulceration: a hypothesis. *J Vasc Surg*. 1991;13:491–495.
233. McMullin GM, Coleridge-Smith PD, Scurr JH. A study of tourniquets in the investigation of venous insufficiency. *Phlebology*. 1990;6:133–139.
234. Nicolaides AN, Hussein MK, Szendro G, et al. The relation of venous ulceration with ambulatory venous pressure measurements. *J Vasc Surg*. 1993;17:414–419.
235. Nicolaides AN. Diagnostic evaluation of patients with chronic venous insufficiency. In: Rutherford R, ed. *Vascular Surgery*, 3rd ed. Philadelphia, Pa: WB Saunders; 1989:1583–1601.
236. Albrechtsson U, Einarsson E, Eklof B. Femoral vein pressure measurements for evaluation of venous function in patients with post-thrombotic iliac veins. *Cardiovasc Interv Radiol*. 1981;4:43–50.
237. May R. Beckenvenendruckmessung. In: May R, Kriessmann A, eds. *Periphere Venendruckmessung*. Stuttgart, Germany: Georg Thieme Verlag; 1978:37–40.
238. Masuda EM, Eklof B, Kistner RL. Direct venous pressure: role in the assessment of venous disease. In: Głowiczki P, Yao JST. *Handbook of Venous Disorders*. London, UK: Chapman and Hall Medical; 1996: 168–177.
239. Negus D, Cockett FB. Femoral vein pressures in post-phlebotic iliac vein obstruction. *Br J Surg*. 1967;54:522–525.
240. Głowiczki P, Pairolo PC, Toomey BJ, et al. Reconstruction of large veins for nonmalignant venous occlusive disease. *J Vasc Surg*. 1992; 16:750–761.
241. Raju S. New approaches to the diagnosis and treatment of venous obstruction. *J Vasc Surg*. 1986;4:42–54.
242. Raju S. A pressure-based technique for the detection of acute and chronic venous obstruction. *Phlebology*. 1988;3:207–216.

243. Illig KA, Ouriel K, De Weese JA, et al. Increasing the sensitivity of diagnosis of chronic venous obstruction. *J Vasc Surg.* 1996;24:176–178.
244. Gruss JD, Heimer W. Bypass procedures for venous obstruction: Palma and May-Husni bypasses, Raju perforator bypass, prosthetic bypasses, primary and adjunctive AV fistulae. In: Raju S, Villavicencio JL, eds. *Surgical Management of Venous Diseases.* Baltimore, Md: Williams & Wilkins; 1997.
245. Nicolaides AN, Sumner DS, eds. *Investigation of Patients With Deep Vein Thrombosis and Chronic Venous Insufficiency.* London, UK: Med-Orion; 1991:39–43.
246. Neglen P, Raju S. Detection of outflow obstruction in chronic venous insufficiency. *J Vasc Surg.* 1993;17:583–589.
247. Abramowitz HB, Queral LA, Flinn WR, et al. The use of photoplethysmography in the assessment of venous insufficiency: a comparison to venous pressure measurements. *Surgery.* 1979;86:434–441.
248. Wienert V, Blazek V. Eine neue Methode zur unblutigen dynamischen Venendruckmessung. *Hautarzt.* 1982;33:498–501.
249. May R, Stemmer R. *Die Licht-Reflexions-Rheographie.* Erlangen, Germany: Perimed; 1984.
250. Partsch H, Gisel I. Funktionelle Indikation zur Krampfaderoperation (stripping). *Wien Klin Wochenschr.* 1977;89:627–632.
251. Hübner K. Is the light reflection rheography (LRR) suitable as a diagnostic method for the phlebology practice? *Phlebol Proctol.* 1986;15:209–212.
252. Nicolaides AN, Miles C. Photoplethysmography in the assessment of venous insufficiency. *J Vasc Surg.* 1987;5:405–412.
253. Blazek V, Schultz-Ehrenburg U. *Quantitative Photoplethysmography: Basic Facts and Examination Tests for Evaluating Peripheral Vascular Functions.* Düsseldorf, Germany: VDI Verlag Düsseldorf; 1996.
254. Weindorf N, Schultz-Ehrenburg U. Der Wert der Photoplethysmographie (Licht-Reflexions-Rheographie) in der Phlebologie. *Vasa.* 1986;15:397–406.
255. Kerner J, Schultz-Ehrenburg U, Lechner W. Quantitative Photoplethysmographie bei gesunden Erwachsenen, Kindern und Schwangeren und bei Varizenpatienten. *Phlebologie.* 1992;21:134–139.
256. Schultz-Ehrenburg U, Blazek V. New possibilities for photoplethysmography. *Phlebol Dig.* 1993;5:5–11.
257. Schultz-Ehrenburg U, Blazek V. Quantitative digital photoplethysmography (D-PPG): first results with on line registration and significance of V0 (venous pump power). In: Schultz-Ehrenburg U, Blazek V, eds. *Advances in Computer Aided Noninvasive Vascular Diagnostics.* Düsseldorf, Germany: VDI Verlag Düsseldorf; 1994.
258. Blazek V, Schultz-Ehrenburg U, Fronek A, et al. Quantitative Audio-Photoplethysmographie: Eine effektive Screeningmesstechnik für kontinuierliche, akustische Wiedergabe peripherer Blutvolumenpulse. *Phlebologie.* 1996;25:158–164.
259. Mühl Th. LRR and invasive Venendruckmessung: Vergleich der Methoden anhand von Simultannessungen. In: May R, Stemmer R, eds. *Die Licht-Reflexions-Rheographie.* Erlangen, Germany: Perimed Verlag; 1984.
260. Shepard AD, Mackey WE, O'Donnell TF. Correlation of venous pressure measurement with LRR. In: May R, Stemmer R, eds. *Die Licht-Reflexions-Rheographie.* Erlangen, Germany: Perimed Verlag; 1984.
261. Partsch H. Volumenmessung (Plethysmographie). In: Simon H, Schoop W, eds. *Diagnostik in der Kardiologie und Angiologie.* Stuttgart, Germany: Georg Thieme Verlag; 1986:526–539.
262. Van Bemmelen PS, Van Ramshort B, Eikelboom BC. Photoplethysmography reexamined: lack of correlation with duplex scanning. *Surgery.* 1992;112:544–548.
263. Bays RA, Healy DA, Atnip RG, et al. Validation of air plethysmography, photoplethysmography and duplex ultrasonography in the evaluation of severe venous stasis. *J Vasc Surg.* 1994;20:721–727.
264. Rosfors S, Lamke LA, Nordstrom E, et al. Severity and location of venous valvular incompetence of distal valve function. *Acta Chir Scand.* 1990;156:689–694.
265. Carrión O, Ley J, Calderón E, et al. La exploración no invasiva en la insuficiencia venosa crónica. In: Leal J, ed. *Insuficiencia Venosa Crónica de la Pelvis de los Miembros Inferiores.* Madrid, Spain: Mosby/Doyma Libros SA; 1996:61–74.
266. Welch HJ, Faliakou EC, McLaughlin RL, et al. Comparison of descending phlebography with quantitative photoplethysmography, air plethysmography and duplex quantitative valve closure time in assessing deep venous reflux. *J Vasc Surg.* 1992;16:913–919.
267. Tiedjen KV, Schultz-Ehrenburg U. Optische Venenverschlußplethysmographie (OVP) am Röntgenkippisch-vergleichende Untersuchungen venöser Abstromverhältnisse. In: Blazek V, Schultz-Ehrenburg U, eds. *Fortschritte in der computerunterstützten nichtinvasiven Gefäßdiagnostik.* Düsseldorf, Germany: VDI Verlag Düsseldorf; 1992.
268. Holm J, Nilsson NJ, Scheersten T, et al. Elective surgery for varicose veins. *J Cardiovasc Surg.* 1974;15:565–572.
269. Fernandes E, Fernandes J, Horner J, et al. Ambulatory calf volume plethysmography in the assessment of venous insufficiency. *Br J Surg.* 1982;66:327–330.
270. Mason R, Giron F. Noninvasive evaluation of venous function in chronic venous disease. *Surgery.* 1982;91:312–317.
271. Schanzer H, Lande L, Premus G, et al. Noninvasive evaluation of chronic venous insufficiency. *Arch Surg.* 1984;119:1013–1017.
272. Struckmann JR, Mathiesen FR. A noninvasive plethysmographic method for evaluation of the musculovenous pump in the lower extremities. *Acta Chir Scand.* 1985;15:235–240.
273. Struckmann JR. Assessment of the venous muscle pump function by ambulatory strain gauge plethysmography. *Dan Med Bull.* 1993;4:460–477.
274. Struckmann JR. Ambulatory strain gauge plethysmography: correlation to symptoms and skin changes in patients with venous insufficiency. *Phlebology.* 1987;2:75–80.
275. Vissing SF, Nielsen SL. Regional blood volume in man determined by radiolabelled erythrocytes. *Clin Physiol.* 1988;8:303–308.
276. Struckmann JR, Vissing SF, Hjortso E. Ambulatory strain-gauge plethysmography and blood volume for quantitative assessment of venous insufficiency. *Clin Physiol.* 1992;12:277–285.
277. Baumgartner I, Franzeck UK, Bollinger A. Venous claudication evaluated by ambulatory plethysmography. *Phlebology.* 1992;7:2–6.
278. Struckmann JR, Strange-Vognsen HH, Andersen J, et al. Venous muscle pump function in patients with primary lymphoedema: assessment by ambulatory strain gauge plethysmography. *Br J Surg.* 1986;73:886–887.
279. Struckmann JR, Meiland H, Bagi P, et al. Venous muscle pump function during pregnancy: assessment by ambulatory strain gauge plethysmography. *Acta Obstet Gynecol Scand.* 1990;69:209–215.
280. Christopoulos D, Nicolaides AN, Szendro G. Venous reflux: quantification and correlation with the clinical severity of venous disease. *Br J Surg.* 1988;75:352–356.
281. Christopoulos D, Nicolaides AN. Noninvasive diagnosis and quantification of popliteal reflux in the swollen and ulcerated leg. *J Cardiovasc Surg.* 1988;29:535–539.
282. Harada R, Katz M, Comerota A. A non-invasive screening test to detect “critical” deep venous reflux. *J Vasc Surg.* 1995;22:532–537.
283. Kalodiki E, Nicolaides AN. Quantitative reflux measurements before and after surgical treatment of varicose veins. *Br J Surg.* 1998;85(suppl I):91–92.
284. Christopoulos D, Nicolaides AN, Cook A, et al. Pathogenesis of venous ulceration in relation to the calf muscle pump function. *Surgery.* 1989;106:829–835.
285. Welkie J, Kerr R, Katz M, et al. Can noninvasive venous volume determinations accurately predict ambulatory venous pressure? *J Vasc Tech.* 1991;15:186–190.
286. Christopoulos D, Nicolaides AN, Duffy P, et al. Noninvasive diagnosis and quantification of outflow obstruction in venous disease. *J Cardiovasc Surg.* 1989;30:72–73.
287. Kalodiki E, Nicolaides AN. Air-plethysmography for the detection of acute DVT: new criteria. *Vasc Surg.* 1997;31:123–129.
288. Kalodiki E, Nicolaides AN. Air plethysmography in the detection of past DVT. *Cardiovasc Surg.* 1997;5(suppl I):I-103. Abstract.
289. Yang D, Vavdongen YK, Stacey MC. Variability and reliability of air plethysmographic measurements for the evaluation of chronic venous disease. *J Vasc Surg.* 1997;26:638–642.
290. Christopoulos D, Nicolaides AN, Galloway JMD, et al. Alterations of the calf muscle pump after venous surgery. *Acta Chir Scand.* 1988;suppl 548:43. Abstract.
291. Christopoulos D, Nicolaides AN, Galloway JMD, et al. Objective non-invasive evaluation of venous surgical results. *J Vasc Surg.* 1988;8:683–687.
292. Welch HJ, McLaughlin RL, O'Donnell TF Jr. Femoral vein valvuloplasty: intraoperative angioscopic evaluation and hemodynamic improvement. *J Vasc Surg.* 1992;16:694–700.
293. Simonian SJ. Air-plethysmography is a unique and valuable noninvasive quantitative diagnostic venous function test for patients with superficial reflux and chronic venous insufficiency. *Phlebology.* 1992;1:627–632.

294. Gillespie DL, Cordts PR, Hartono C, et al. The role of plethysmography in monitoring the results of venous surgery. *J Vasc Surg.* 1992;16:674–678.
295. Bry JD, Muto PA, O'Donnell TF, et al. The clinical and hemodynamic results after axillary-to-popliteal vein valve transplantation. *J Vasc Surg.* 1995;21:110–119.
296. Christopoulos D, Nicolaides AN. Long term effect of elastic compression on venous haemodynamics of the leg. *Br J Surg.* 1989;76:647.
297. Christopoulos D, Nicolaides AN, Belcaro G, et al. The effect of elastic compression on calf muscle pump function. *Phlebology.* 1990;5:13–19.
298. Menzinger G, Horakowa M, Mayer W, et al. Reduction of venous reflux by compression: a comparison between short and long stretch material. *Phlebology.* 1995;suppl 1:888–891.
299. Christopoulos D, Nicolaides AN, Belcaro G, et al. Venous hypertensive microangiopathy in relation to clinical severity and effect of elastic compression. *J Dermatol Surg Oncol.* 1991;17:809–813.
300. Labropoulos N, Leon M, Geroulakos G, et al. Venous hemodynamic abnormalities in patients with leg ulceration. *Am J Surg.* 1995;169:572–574.
301. Christopoulos D, Nicolaides AN. Hemodynamic factors responsible for venous ulceration. *Angiologie.* 1988;39:401–403.
302. Welkie JF, Comerota AJ, Katz ML, et al. Haemodynamic deterioration in chronic venous disease. *J Vasc Surg.* 1992;16:733–740.
303. Schalin L. Arteriovenous communications in varicose veins localised by thermography and identified by operative microscopy. *Acta Chir Scand.* 1981;147:409–420.
304. Haimovici H. Role of precapillary arteriovenous shunting in the pathogenesis of varicose veins and its therapeutic implications. *Surgery.* 1987;101:512–522.
305. Thulesius O, Norgren L, Gjöres JE. Foot volumetry: a new method for objective assessment of oedema and venous function. *Vasa.* 1973;2:325–329.
306. Norgren L. Functional evaluation of chronic venous insufficiency by foot volumetry. *Acta Chir Scand.* 1974;444(suppl):1–48.
307. Norgren L, Thulesius O, Gjores JE, et al. Foot-volumetry and simultaneous venous pressure measurements for evaluation of venous insufficiency. *Vasa.* 1974;3:140–147.
308. Lawrence D, Kakkar VV. Venous pressure measurement and foot volumetry in venous disease. In: Verstraete M, ed. *Techniques in Angiology.* The Hague, the Netherlands: Martinus Nijhoff, NV; 1979.
309. Norgren L, Thulesius O. Pressure volume characteristics of foot veins in normal cases and patients with venous insufficiency. *Blood Vessels.* 1975;12:1–12.
310. Lawrence D, Kakkar VV. Post-phlebotic syndrome: a functional assessment. *Br J Surg.* 1980;67:686–689.
311. Partsch H, Kahn P. Venöse Strömungsbeschleunigung in Bein und Becken durch "Anti Thrombosestrümpfe." *Klinikerzt.* 1982;11:609–615.
312. Oburger K, Partsch H, Wruhs M. Sprunggelenkskontraktur bei Patienten mit Unterschenkelgeschwüren. *Wien Med Wochenschr.* 1988;138:38–40.
313. Norgren L. Foot volumetry before and after surgical treatment of patients with varicose veins. *Acta Chir Scand.* 1975;141:129–134.
314. Stöberl C, Gabler S, Partsch H. Indikationsgerichte bestumpfung; messung der venösen pumfunktion. *Vasa.* 1989;18:35–39.
315. Partsch H. Improvement of venous pumping in chronic venous insufficiency by compression dependent on pressure and material. *Vasa.* 1984;13:58–64.
316. Partsch H, Mostbeck A. Constriction of varicose veins and improvement of venous pumping by dihydroergotamine. *Vasa.* 1985;14:74–80.
317. Norgren L, Gjores E. Venous function in previously thrombosed legs: a follow-up study of streptokinase treated patients. *Acta Chir Scand.* 1977;143:421–424.
318. Norgren L, Widmer LK. Venous function, evaluated by foot volumetry, in patients with a previous deep venous thrombosis, treated with streptokinase: preliminary results. *Vasa.* 1978;7:412–414.
319. Partsch H. From thrombosis to post-thrombotic syndrome: plethysmographic studies of venous function. *Wien Med Wochenschr.* 1994;144:226–268.
320. Schulman S, Granqvist S, Juhlin-Dannfelt A, et al. Long-term sequelae of calf vein thrombosis treated with heparin or low dose streptokinase. *Acta Med Scand.* 1986;219:349–357.
321. Swedenborg J, Hagglof R, Jacobsson H, et al. Results of surgical treatment for iliofemoral venous thrombosis. *Br J Surg.* 1986;73:871–874.
322. Plate G, Eklöf B, Norgren L, et al. Venous thrombectomy for iliofemoral vein thrombosis: 10 year results of a prospective randomised study. *Eur J Vasc Endovasc Surg.* 1997;14:367–374.
323. Nilsson L, Austrell C, Norgren L. Venous function during late pregnancy, the effect of elastic compression hosiery. *Vasa.* 1992;21:203–205.
324. Austrell C, Nilsson L, Norgren L. Maternal and fetal hemodynamics during late pregnancy: effect of compression hosiery treatment. *Phlebology.* 1993;8:155–157.
325. Austrell C, Thalín I, Norgren L. The effects of long term graduated compression on venous function during pregnancy. *Phlebology.* 1995;10:165–168.
326. Lewis JD, Parsons DCS, Needham TN, et al. The use of venous pressure measurements and directional Doppler recordings in distinguishing between superficial and deep valvular incompetence in patients with deep venous insufficiency. *Br J Surg.* 1973;60:312.
327. Barnes RW, Ross EA, Strandness DE. Differentiation of primary from secondary varicose veins by Doppler ultrasound and strain gauge plethysmography. *Surg Gynecol Obstet.* 1975;141:207–211.
328. Shull KC, Nicolaides AN, Fernandes FJ, et al. Significance of popliteal reflux in relation to ambulatory venous pressure and ulceration. *Arch Surg.* 1975;114:1304–1306.
329. Nicolaides AN, Fernandes e Fernandes J, et al. Doppler ultrasound in the investigation of venous insufficiency. In: Nicolaides AN, Yao JST, eds. *Investigation of Vascular Disorders.* London, UK: Churchill Livingstone; 1981:478–487.
330. Kriessman A, Bollinger A, Keller H. *Praxis der Doppler-Sonographie.* Stuttgart, Germany/New York, NY: G Thieme; 1982.
331. Partsch H, Löffler O. Studies of the venous reflux from the lower limb using a direct ultrasonic detector. *Wien Klin Wochenschr.* 1971;83:781–789.
332. Folse R, Alexander RH. Directional flow detection for localizing venous valvular incompetency. *Surgery.* 1970;67:114–121.
333. Miller SS, Foote AV. The ultrasonic detection of incompetent perforating veins. *Br J Surg.* 1974;61:653–656.
334. O' Donnell TF, Burnand KG, Clemenson G, et al. Doppler examination vs clinical and phlebographic detection of the location of incompetent perforating veins: a prospective study. *Arch Surg.* 1977;112:31–35.
335. Hoare MC, Royle JP. Doppler ultrasound detection of saphenofemoral and saphenopopliteal incompetence and operative venography to ensure precise saphenopopliteal ligation. *Aust NZ J Surg.* 1984;54:49–52.
336. Vasdekis SN, Clark H, Nicolaides AN. Quantification of venous reflux by means of duplex scanning. *J Vasc Surg.* 1989;10:670–677.
337. Jeanneret Ch, Labs KH, Aschwanden M, et al. Physiological reflux and venous diameter change in the proximal lower limb veins during a standardised Valsava manoeuvre. *Eur J Vasc Endovasc Surg.* 1999;17:398–403.
338. Czeredarczuk M, Branas CC, Weingarten MS. Duplex imaging and distal calf deflation to measure venous reflux time. *J Vasc Technol.* 1991;15:297–299.
339. Iafrafi MD, Welch HJ, O'Donnell TF, et al. Correlation of venous noninvasive tests with the Society for Vascular Surgery/International Society for Cardiovascular Surgery clinical classification of chronic venous insufficiency. *J Vasc Surg.* 1994;19:1001–1007.
340. Criado E, Daniel PF, Marston W, et al. Physiologic variations in lower extremity venous valvular function. *Ann Vasc Surg.* 1995;9:102–108.
341. Welch HJ, Young CM, Semegran AB, et al. Duplex assessment of venous reflux and chronic venous insufficiency: the significance of deep venous reflux. *J Vasc Surg.* 1996;24:755–762.
342. Rodriguez AA, Whitehead CM, McLaughlin RL, et al. Duplex-derived valve closure times fail to correlate with reflux flow volumes in patients with chronic venous insufficiency. *J Vasc Surg.* 1995;23:606–610.
343. Anderson J, Thurin A, Thulesius O. Valvular function of peripheral veins after hyperemic dilation. *J Vasc Surg.* 1996;23:611–615.
344. Beckwith T, Richardson G, Sheldon M, et al. A correlation between blood flow volume and ultrasonic Doppler wave forms in the study of valve efficiency. *Phlebology.* 1993;8:12–16.
345. Rutgers PA, Kitslaar PJ, Ermers EJ. Photoplethysmography in the diagnosis of superficial venous valvular incompetence. *Br J Surg.* 1993;80:351–353.
346. Pflug JJ, Zubac DP, Kersten DR, et al. The resting interstitial tissue pressure in primary varicose veins. *J Vasc Surg.* 1990;11:411–417.
347. Moreno AH, Katz AI, Gold LD, et al. Mechanics of distension of dog veins and other thin walled tubular structures. *Circ Res.* 1970;27:1069–1080.

348. Ludbrook J, Loughlin J. Regulation of volume in postarteriolar vessels of the lower limb. *Am Heart J*. 1964;67:493-507.
349. Webb-Peploe MM, Shepherd JT. Veins and their control. *N Engl J Med*. 1968;278:317-322.
350. Webb-Peploe MM, Shepherd JT. Response of large hindlimb veins of the dog to sympathetic nerve stimulation. *Am J Physiol*. 1968;215:299-307.
351. Öberg B. The relationship between active constriction and passive recoil of the veins at various distending pressures. *Acta Physiol Scand*. 1967;71:233-247.
352. Shepherd JT. Role of the veins in the circulation. *Circulation*. 1966;33:484-491.
353. Vanhoutte PM, Shepherd JT. Thermosensitivity and veins. *J Physiol (Paris)*. 1971;63:449-451.
354. Meissner MH, Manzo RA, Bergelin RO, et al. Venous diameter and compliance after deep venous thrombosis. *Thromb Haemost*. 1994;72:372-376.
355. Comerota AJ, Stewart GJ. Venous tone regulatory mechanisms: what's new? *Int Angiol*. 1995;14(suppl 1):1-7.
356. Zamboni P, Marcellino MG, Portaluppi F, et al. The relationship between *in vitro* and *in vivo* venous compliance measurement. *Int Angiol*. 1996;15:149-52.
357. Neglen P, Raju S. The pressure/volume relationship of the calf: a measurement of vein compliance? *J Cardiovasc Surg*. 1995;36:219-224.
358. Dahn I, Eriksson E. Plethysmographic diagnosis of deep venous thrombosis of the leg. *Acta Chir Scand*. 1968;398(suppl):33-42.
359. Thulesius O, Gjöres JE. Reactions of venous smooth muscle in normal men and patients with varicose veins. *Angiology*. 1974;25:145-154.
360. Neglen P, Raju S. Compliance of the normal and post thrombotic calf. *J Cardiovasc Surg*. 1995;36:225-231.
361. Aellig WH. Clinical pharmacology, physiology and pathophysiology of superficial veins. *Br J Clin Pharmacol*. 1994;38:181-196.
362. Clarke GH, Vasdekis SN, Hobbs JT, et al. Venous wall function in the pathogenesis of varicose veins. *Surgery*. 1992;111:402-408.
363. Chauveau M. Medical treatment of chronic venous insufficiency: pharmaco-clinical assessment. *Presse Med*. 1994;23:243-249.
364. Tsouderos Y. Venous tone: are the phlebotonic properties predictive of a therapeutic benefit? A comprehensive view of our experience with Daflon 500 mg. *Z Kardiol*. 1991;80(suppl 7):95-101.
365. Struckmann JR, Nicolaides AN. Flavonoids: a review of Daflon 500 mg in patients with chronic venous insufficiency and related disorders. *Angiology*. 1994;45:419-427.
366. Szendro G, Veller M, Fisher C, et al. The effect of elastic compression on the venous tone in patients with varicose veins. *Vasa*. 1992;21:198-202.
367. Harris B, Eaglstein WH, Falanga V. Basal cell carcinoma arising in venous ulcers and mimicking granulation tissue. *J Dermatol Surg Oncol*. 1993;19:150-152.
368. Gosain A, Sanger JR, Yousif NJ, et al. Basal cell carcinoma of the lower leg occurring in association with chronic venous stasis. *Ann Plast Surg*. 1991;26:279-283.
369. Leu HJ. Morphology of chronic venous insufficiency: light and electron microscopic examinations. *Vasa*. 1991;20:330-342.
370. Vanscheidt W, Laaf H, Weiss JM, et al. Immunohistochemical investigation of dermal capillaries in chronic venous insufficiency. *Acta Derm Venereol*. 1991;71:17-19.
371. Laaf H, Vandscheidt W, Weiss JM, et al. Immunohistochemical investigation of pericytes in chronic venous insufficiency. *Vasa*. 1991;20:323-328.
372. Herrick SE, Sloan P, McGurk M, et al. Sequential changes in histologic pattern and extracellular matrix deposition during the healing of chronic venous ulcers. *Am J Pathol*. 1992;141:1085-1095.
373. Skelsi R, Skelsi L, Cortinovich R, et al. Morphological changes of dermal blood and lymphatic vessels in chronic venous insufficiency of the leg. *Int Angiol*. 1994;13:308-311.
374. Pappas PJ, Duran WN, Hobson RW II. Pathology and cellular physiology of chronic venous insufficiency. In: Gloviczki P, Yao JST, eds. *Handbook of Venous Disorders*. London, UK: Chapman & Hall Medical; 1996:44-59.
375. Carpentier PH, Colomb M, Brasseur S, et al. Capillary densitometry in chronic venous insufficiency. *J Vasc Res*. 1998;35(suppl 2):19.
376. Bollinger A, Butti P, Barras JP, et al. Red cell velocity in nailfold capillaries of man measured by television microscopy technique. *Microvasc Res*. 1974;7:61-72.
377. Fagrell B, Rosin L, Eriksson S-E. Comparison between a new computerised and an analogue video-photometric, cross-correlation technique for measuring capillary blood cell velocity in humans. *Int J Microcirc Clin Exp*. 1994;14:133-138.
378. Bollinger A, Jager K, Roten A, et al. Diffusion, pericapillary distribution and clearance of Na-fluorescein in the human nailfold. *Pflugers Arch*. 1979;382:137-143.
379. Bollinger A, Pfister G, Hoffmann U, et al. Fluorescence microlymphography in chronic venous insufficiency. *Int Angiol*. 1981;8:23-26.
380. Speiser DE, Bollinger A. Microangiopathy in mild chronic venous incompetence (CVI): morphological alterations and increased transcapillary diffusion detected by fluorescence videomicroscopy. *Int J Microcirc*. 1991;10:55-66.
381. Haselbach P, Vollenweider U, Moneta G. Microangiopathy in severe chronic venous insufficiency evaluated by fluorescence videomicroscopy. *Phlebology*. 1986;1:159-169.
382. Belcaro G, Hoffmann U, Bollinger A, et al, eds. *Laser Doppler*. London, UK/Los Angeles, Calif: Med-Orion Publishing Company; 1994.
383. Stern MD. In vivo evaluation of microcirculation by coherent light scattering. *Nature*. 1975;254:56-58.
384. Nilsson GE, Tenland T, Ortega PA. Evaluation of laser Doppler flowmeter for measurement of tissue blood flow. *IEEE Trans Biomed Eng*. 1980;27:597-604.
385. Saumet JL, Dittmar A, Leftheriotis G. Noninvasive measurements of skin blood flow: comparison between plethysmography, laser Doppler flowmeter and heat thermal clearance method. *Int J Microcirc Clin Exp*. 1986;5:73-83.
386. Johnson JM, Taylor WF, Shepard AP, et al. Laser Doppler measurement of skin blood flow: comparison with plethysmography. *J Appl Physiol*. 1984;56:798-803.
387. Hoffmann U, Edwards JM, Franzeck UK, et al. The frequency histogram: a new method for the evaluation of laser Doppler flux motion. *Microvasc Res*. 1990;40:293-301.
388. Chittenden SJ, Shami SK, Cheate TR, et al. Vasomotion in the leg skin of patients with chronic venous insufficiency. *Vasa*. 1992;21:138-142.
389. Jochmann W, Mostbeck A, Partsch H. Postocclusive reactive hyperaemia and postural vasoconstriction in different kinds of leg ulcers: investigations with laser Doppler. *Vasa*. 1993;22:306-315.
390. Belcaro G, Grigg M, Vasdekis S, et al. Evaluation of the effects of elastic compression in patients with post-phlebotic limbs by laser-Doppler flowmetry. *Phlebologie*. 1988;41:797-802.
391. Belcaro GV, Nicolaides AN. Effects of intermittent sequential compression in venous hypertensive microangiopathy. *Phlebology*. 1994;9:99-103.
392. Franzeck UK, Huch A, Zimmermann AR, et al. A triple electrode for simultaneous investigations of transcutaneous oxygen tension, laser Doppler fluxmetry and dynamic fluorescence video microscopy. *Int J Microcirc Clin Exp*. 1995;14:269-273.
393. Neumann HAM, van Leeuwen M, van den Broek MJTB, et al. Transcutaneous oxygen tension in chronic venous insufficiency syndrome. *Vasa*. 1984;13:213-219.
394. Fischer M, Franzeck UK, Herrig I, et al. Flow velocity of single lymphatic capillaries in human skin. *Am J Physiol*. 1996;270:H358-H363.
395. Wiederhielm CA, Woodbury JK, Kirk S, et al. Pulsatile pressures in the microcirculation of frog's mesentery. *Am J Physiol*. 1964;207:173-176.
396. Intaglietta M, Pawula RF, Tompkins WR. Pressure measurements in the mammalian microvasculature. *Microvasc Res*. 1970;2:212-220.
397. Mahler F, Mukcion MA, Intaglietta M, et al. Blood pressure fluctuations in human nailfold capillaries. *Am J Physiol*. 1979;6:H888-H893.
398. Spiegel M, Vesti B, Shore A, et al. Pressure of lymphatic capillaries in human skin. *Am J Physiol*. 1992;262:H1208-H1210.
399. Zaugg-Vesti B, Dörffler-Melly J, Spiegel M, et al. Lymphatic capillary pressure in patients with primary lymphoedema. *Microvasc Res*. 1993;46:128-134.
400. Allegra C. Lymphatic capillary pressure in human skin of patients with chronic venous insufficiency. *Int J Microcirc Clin Exp*. 1994;14(suppl 1):191.
401. Intaglietta M. Pressure measurements in the microcirculation with active and passive transducers. *Microvasc Res*. 1973;5:317-323.
402. Intaglietta M, Tompkins WR. Simplified micropressure measurements via bridge current feedback. *Microvasc Res*. 1990;39:386-389.
403. Wiig H, Reed RK, Aukland K. Micropuncture measurement of interstitial fluid pressure in rat subcutis and skeletal muscle: comparison to wick-in-needle technique. *Microvasc Res*. 1981;21:308-319.

404. Taylor GW, Kinmonth JB, Rollinson E. Lymphatic circulation studied with radioactive plasma protein. *BMJ*. 1957;1:133-135.
405. Jackson FI, Bowen P, Lentle BC. Scintilymphangiography with Tc-antimony sulphide colloid in hereditary lymphedema. *Clin Nucl Med*. 1978;3:296-300.
406. Sty JR, Starshak RJ. Atlas of pediatric radionuclide lymphography. *Clin Nucl Med*. 1982;7:428-433.
407. Stewart G, Gaunt JI, Croft DN, et al. Isotope lymphography: a new method of investigating the role of the lymphatics in chronic limb oedema. *Br J Surg*. 1985;72:906-909.
408. Nawaz K, Hamad MM, Sadek S, et al. Dynamic lymph flow imaging in lymphedema: normal and abnormal patterns. *Clin Nucl Med*. 1986;11:653-658.
409. Vaqueiro M, Gloviczki P, Fisher J, et al. Lymphoscintigraphy in lymphedema: an aid to microsurgery. *J Nucl Med*. 1986;27:1125-1130.
410. Weissleder H, Weissleder R. Lymphedema: evaluation of qualitative and quantitative lymphoscintigraphy in 238 patients. *Radiology*. 1988;167:729-735.
411. Collins PS, Villavicencio JL, Abreu SH, et al. Abnormalities of lymphatic drainage in lower extremities: a lymphoscintigraphic study. *J Vasc Surg*. 1989;9:145-152.
412. Gloviczki P, Calcagno D, Schirger A, et al. Noninvasive evaluation of the swollen extremity: experiences with 190 lymphoscintigraphic examinations. *J Vasc Surg*. 1989;9:683-690.
413. Cambria RA, Gloviczki P, Naessens JM, et al. Noninvasive evaluation of the lymphatic system with lymphoscintigraphy: a prospective, semi-quantitative analysis in 386 extremities. *J Vasc Surg*. 1993;18:773-782.
414. Mostbeck A, Kahn P, Partsch H. Quantitative lymphography in lymphoedema. In: Bollinger A, Partsch A, Wolfe JHN, eds. *The Initial Lymphatics*. Stuttgart, Germany: G Thieme; 1985:123-130.
415. Kleinhans E, Baumeister RG, Hahn D, et al. Evaluation of transport kinetics in lymphoscintigraphy: follow-up study in patients with transplanted lymphatic vessels. *Eur J Nucl Med*. 1985;10:349-352.
416. Partsch H. Lymphangiopathie bei chronischer veneninsuffizienz. *Phlebol Proctol*. 1984;13:85-89.
417. Partsch H. Assessment of abnormal lymph drainage for the diagnosis of lymphoedema by isotopic lymphangiography and by indirect lymphography. *Clin Dermatol*. 1995;13:445-450.
418. Bull RH, Gane JN, Evans JE, et al. Abnormal lymph drainage in patients with chronic venous leg ulcers. *J Am Acad Dermatol*. 1993;28:585-590.
419. Hach W, Schirmers U, Becker L. Veränderungen der tiefen Leitvenen bei einer Stammvaricose der V. saphena magna. In: Muller-Wiefel H, ed. *Mikrozirkulation und Blut rheologie*. Baden, Germany: Witzstrock; 1980.
420. Partsch H. "Betterable" and "nonbetterable" chronic venous insufficiency: a proposal for a practice oriented classification. *Vasa*. 1980;9:165-167.
421. Molokhia FA. A proposal for a new classification of occlusive venous diseases of lower limbs. *Alexandria Med J*. 1981;27:76-81.
422. Sytchev GG. Classification of chronic venous disorders of lower extremities and pelvis. *Int Angiol*. 1985;4:203-206.
423. Pierchalla P, Tronnier H. Diagnosis and classification of venous insufficiency of the leg. *Dtsch Med Wochenschr*. 1985;110:1700-1702.
424. Porter JP, Rutherford RB, Clagett GP, et al. Reporting standards in venous disease. *J Vasc Surg*. 1988;8:172-181.
425. Cornu-Thénard A, De Vincenzi G, Maraval M. Evaluation of different systems for clinical quantification of varicose veins. *J Dermatol Surg Oncol*. 1991;17:345-348.
426. Enrici EA, Caldevilla HS. Classification de la insuficiencia venosa cronica. In: Enrici EA, Caldevilla HS, eds. *Insuficiencia Venosa Cronica de los Miembros Inferiores*. Buenos Aires, Argentina: Editorial Celcius; 1992:107-114.
427. Miranda C, Fabre M, Meyer P, et al. Evaluation of a reference anatomical classification of varices of the lower limbs. *Phlebologie*. 1993;46:235-239.
428. Nicolaidis AN, Eklof B, Bergan JJ, et al. Classification and grading of chronic venous disease in the lower limbs: a consensus statement. *Phlebologie*. 1995;10:42-45.
429. Porter JM, Moneta GL. International Consensus Committee on Chronic Venous Disease: reporting standards in venous disease: an update. *J Vasc Surg*. 1995;2:635-645.
430. Cornu-Thénard A, Boivin P, Garde C, et al. Évaluation des résultats des thérapeutiques curatives des varices par trois scores: clinique, Doppler et échographique. *Phlébologie*. 1992;4:389-399.
431. DePalma R, Kowallek DL. Venous ulceration: a cross-over study from non-operative to operative treatment. *J Vasc Surg*. 1996;24:788-792.
432. Kistner RL, Eklof B, Masuda EM. Diagnosis of chronic venous disease of the lower extremities: the "CEAP" classification. *Mayo Clin Proc*. 1996;71:338-345.
433. Gloviczki P, Bergan JJ, Menawat SS, et al. Safety, feasibility and early efficacy of Subfascial Endoscopic Perforator Surgery (SEPS): a preliminary report from the North American Registry. *J Vasc Surg*. 1997;25:94-105.
434. Labropoulos N. CEAP in clinical practice. *Vasc Surg*. 1997;31:224-225.
435. Gniadecka M. Dermal oedema in lipodermatosclerosis: distribution, effects of posture and compressive therapy evaluated by high frequency ultrasonography. *Acta Dermatol Venereol*. 1995;75:120-124.
436. Falanga V, Bucalo B. Use of a durometer to assess skin hardness. *J Am Acad Dermatol*. 1993;29:47-51.
437. Falanga V, Moosa HH, Nemeth AJ, et al. Dermal pre-capillary fibrin in venous disease and venous ulceration. *Arch Dermatol*. 1987;123:620-623.
438. Keates JS, Fitzgerald DE. Limb volume and blood flow changes during the menstrual cycle. *Angiology*. 1969;20:618-627.
439. Fowkes FGR, Bosanquet N, Franks PJ, et al. Proposal of a consensus statement: the role of oedema-protective agents in the treatment of chronic venous insufficiency. *Phlebology*. 1996;11:39-40.
440. Barnes MD, Mani R, Barrett DF, et al. How to measure changes in oedema in patients with chronic venous ulcers. *Phlebology*. 1992;7:31-35.
441. Vayssairat M, Maurel A, Gouny P, et al. La volumetrie: une methode precise de quantification en phlebologie. *J Mal Vasc*. 1994;19:108-110.
442. Grenier E, Fischbach JU, Mönter B, et al. Objektivierung des Lymphödems nach Mastektomie. *Deutsche Med Wochenschr*. 1985;110:949-952.
443. Bellinger OK, Kirchmaier CM, Breddin H K. Objektivierung der Odemneigung an Venenkranken und Venengesunden mittels optoelektronischer Volumetrie. *Vasa*. 1991;33(suppl):324-326.
444. Blume J, Langenbahn H, Champvallins M. Quantification of oedema using the volometer technique: therapeutic application of Daflon 500 mg in chronic venous insufficiency. *Phlebologie*. 1992;2(suppl):37-40.
445. Bednarczyk JH, Hershler C, Cooper DG. Development and clinical evaluation of computerized limb volume measurement system (CLEMS). *Arch Phys Med Rehabil*. 1992;73:60-63.
446. Schmidt C. La volumétrie opto-électronique, une autre méthode de quantification de l'oedeme. *J Mal Vasc*. 1994;19:326-327.
447. Veraart JCJM, Neumann HAM. Leg volume measurements with a modified optoelectronic measurement system. *Phlebologie*. 1995;10:62-64.
448. Vayssairat M, Maurel A, Gouny P. Leg volume measurements. *Phlebologie*. 1995;10:173-174.
449. Hands L, Collin J. Legs that swell and ache: volume changes during the day in healthy young adults. *BMJ*. 1984;288:447-448.
450. Vayssairat M, Debure C, Maurel A, et al. Horse-chestnut seed extract for chronic venous insufficiency. *Lancet*. 1996;347:1182.
451. Speakman MJ, Collin J. Are swelling and aching of the legs reduced by operation on varicose veins? *BMJ*. 1986;293:105-106.
452. Nocker W, Diebschlag W, Lehmaner W. 3-Monatige, randomisierte doppelblinde Dosis-Wirkungsstudie mit O-(Beta-Hydroxyäthyl)-rutosid-Trinklösungen. *Vasa*. 1989;18:235-238.
453. Rehn D, Hennings G, Nocker W, et al. Time course of the anti-oedematous effect of O-(β -hydroxyethyl)-rutosides in healthy volunteers. *Eur J Clin Pharmacol*. 1991;40:625-627.
454. Casley-Smith JR, Morgan RG, Piller NB. Treatment of lymphedema of the arms and legs with 5,6-benzo-alpha pyrone. *N Engl J Med*. 1993;329:1158-1163.
455. Diehm C, Trampisch HJ, Lange S, et al. Comparison of leg compression stocking and oral horse-chestnut seed extract therapy in patients with chronic venous insufficiency. *Lancet*. 1996;347:292-294.
456. Berard A, Kurz X, Zuccarelli F, et al. Reliability study of the Leg-O-Meter, an improved tape measure device, in patients with chronic venous insufficiency of the leg. VEINES group. *Angiology*. 1998;49:169-173.
457. Tierney S, Aslam M, Rennie K, et al. Infrared optoelectronic volumetry: the ideal way to measure leg volume. *Eur J Vasc Endov Surg*. 1996;12:412-417.
458. Fegan WG, Fitzgerald DE, Beesley WH. Modern approach to the injection treatment of varicose veins. *Am Heart J*. 1964;68:557-564.

459. Browse NL, Burnand KG, Thomas ML, eds. *Diseases of the Veins*. London: Edward Arnold; 1988:chapters 3 and 11.
460. Alimi YS, Barthelemy P, Juhan C. Venous pump of the calf: a study of venous and muscular pressures. *J Vasc Surg*. 1994;20:728–735.
461. Tierney S, Burke P, Fitzgerald P, et al. Ankle fracture is associated with prolonged venous dysfunction. *Br J Surg*. 1993;80:36–38.
462. Solomon C, Munro AR, Van Rij AM, et al. The use of video image analysis for the measurement of venous ulcers. *Br J Dermatol*. 1995;133:565–570.
463. Gilman TH. Parameter for measurement of wound closure. *Wounds*. 1990;3:95–101.
464. Martin M. Dynamic wound healing profile of venous ulcer cruris. *Vasa*. 1994;23:228–233.
465. Ibbotson SH, Layton AM, Davies JA, et al. The effect of aspirin on haemostatic activity in the treatment of chronic venous ulceration. *Br J Dermatol*. 1995;132:422–426.
466. Gorin DR, Cordts PR, LaMorte WW, et al. The influence of wound geometry on the measurement of wound healing rates in clinical trials. *J Vasc Surg*. 1996;23:524–528.
467. Gorin DR, LaMorte WW, Barry M, et al. Is complete wound healing a valid end point for clinical trials of venous stasis ulcer treatment? *Vasc Surg*. 1997;31:163–169.
468. Teepe RGC, Roseuw DI, Hermans J, et al. Randomized trial comparing cryopreserved cultured epidermal allografts with hydrocolloid dressings in healing chronic venous ulcers. *J Am Acad Dermatol*. 1993;29:982–988.
469. Margolis DJ, Gross EA, Wood CR, et al. Planimetric rate of healing in venous ulcers of the leg treated with pressure bandage and hydrocolloid dressing. *J Am Acad Dermatol*. 1993;28:418–421.
470. Burnand K, Clemenson G, Morland M, et al. Venous lipodermatosclerosis: treatment by fibrinolytic enhancement and elastic compression. *BMJ*. 1980;280:7–11.
471. Languillat N, Vecchiali JF, Zuccarelli F, et al. Essai en double aveugle contre placebo des effets du Vasobral dans les troubles de la perméabilité capillaire liés à l'insuffisance veineuse par le test isotopique de Landis. *Angiology*. 1986;39:1–4.
472. Laurent R, Gilly R, Frileux C. Clinical evaluation of a venotropic drug in man: example of Daflon 500 mg. *Int Angiol*. 1988;7(suppl to No. 2):39–43.
473. Renton S, Leon M, Belcaro G, et al. The effect of hydroxyethylrutosides on capillary filtration in moderate venous hypertension. *Int Angiol*. 1994;13:259–262.
474. Garratt AM, Ruta DA, Abdalla MI, et al. The SF 36 health survey questionnaire: an outcome measure suitable for routine use within the NHS? *BMJ*. 1993;306:1440–1444.
475. Price P, Harding K. Quality of life. *Lancet*. 1995;346:445. Letter.
476. Hyland ME, Thomson B. Quality of life of leg ulcer patients: questionnaire and preliminary findings. *J Wound Care*. 1994;3:294–298.
477. Launois R, Rebpi-Marty J, Henry B. Construction and validation of a quality of life questionnaire in chronic lower limb venous insufficiency (CIVIQ). *Qual Life Res*. 1996;5:539–554.
478. Comerota AJ, Harada RN, Eze AR, et al. Air plethysmography: a clinical review. *Int Angiol*. 1995;14:45–52.
479. Hendricks WM, Swallow RT. Management of stasis leg ulcers with Unna's boots versus elastic support stockings. *J Am Acad Dermatol*. 1985;12:90–98.
480. Callam MJ, Harper DR, Dale JJ, et al. Lothian and Forth Valley Leg Ulcer Healing Trial, part 1: elastic versus non-elastic bandaging in the treatment of chronic leg ulceration. *Phlebology*. 1992;7:136–141.
481. Samson RH. Compression stockings and non-continuous use of polyurethane foam dressings for the treatment of venous ulceration. *J Dermatol Surg Oncol*. 1993;19:68–72.
482. Coleridge-Smith P, Sarin S, Hasty J, et al. Sequential gradient pneumatic compression enhances venous ulcer healing: a randomised trial. *Surgery*. 1990;108:971–975.
483. Mayer W, Jochmann W, Partsch H. Leg-ulcer: healing by conservative management: a prospective study. *Wien Med Wochenschr*. 1994;144:250–252.
484. Moffat CJ, Franks PJ, Oldroyd M, et al. Community clinics for leg ulcers and impact of healing. *BMJ*. 1992;305:1389–1392.
485. Blair SD, Wright DDI, Backhouse CM, et al. Sustained compression and healing of chronic venous ulcers. *BMJ*. 1988;297:1159–1161.
486. Partsch H. Pitfalls of venous ulcer trials. *Phlebology*. 1995;11(suppl 1):846–848.
487. Samson RH, Showalter DP. Stockings and the prevention of venous ulcers. *Dermatol Surg*. 1996;22:373–376.
488. Harper DR, Ruckley CV, Dale JJ, et al. Prevention of recurrence of chronic leg ulcer: a randomised trial of different degrees of compression. In: Raymond-Martinbeau P, Prescott R, Zummo M, eds. *Phlebologie*. London, UK: John Libbey; 1992:902–903.
489. Stacey MC, Burnand KG, Layer GT, et al. Calf muscle pump function in patients with healed venous ulcers is not improved by surgery to the communicating veins or by elastic stockings. *Br J Surg*. 1988;75:436–439.
490. Wright DDI, Franks PJ, Blair SD, et al. Oxerutins in the prevention of recurrence in chronic venous ulceration: randomized controlled trial. *Br J Surg*. 1991;78:1269–1270.
491. Kikta MJ, Schuler JJ, Meyer JP, et al. A prospective randomised trial of Unna's boots versus hydroactive dressing in the treatment of venous stasis ulcers. *J Vasc Surg*. 1988;7:478–486.
492. Zuccarelli F. Enquete épidémiologique sur les 15 premières nouvelles patientes consultant dans 200 cabinets de phlébologie pour des doubleurs liées à une insuffisance veineuse des membres inférieurs. *Artères Veines*. 1990;9:724–727.
493. Partsch H. Compression of the legs. *J Dermatol Surg Oncol*. 1991;17:799–805.
494. Macklon NS, Greer IA. Technical note: compression stockings and posture: a comparative study of their effects on the proximal deep veins of the leg at rest. *Br J Radiol*. 1995;68:515–518.
495. Norgren L, Austrell C, Nilsson L. The effect of graduated elastic compression stockings on femoral blood flow velocity during late pregnancy. *Vasa*. 1995;24:282–285.
496. Emter M, Alexander A. Venous flow in the lower limb with compression therapy: study with the duplex scanner. In: Davy A, Stemmer R, eds. *Phlebologie*. London, UK: John Libbey; 1989:868–870.
497. Labropoulos N, Leon M, Volteas N, et al. Acute and long term effect of elastic stockings in patients with varicose veins. *Int Angiol*. 1994;13:119–123.
498. Sparrow RA, Hardy JG, Fentem PH. Effect of "antiembolism" compression hosiery on leg blood volume. *Br J Surg*. 1995;82:53–59.
499. Samson RH, Scher LA, Gupta SK, et al. Photoplethysmographic evaluation of external compression therapy for chronic venous ulceration. *J Cardiovasc Surg*. 1986;27:24–26.
500. Partsch H. Do we need firm compression stocking exerting high pressure? *Vasa*. 1984;13:52–57.
501. Norgren L. Elastic compression stockings: an evaluation with foot volumetry, strain-gauge plethysmography and photoplethysmography. *Acta Chir Scand*. 1988;154:505–507.
502. Struckmann JR. Low compression, high gradient stockings in patients with venous insufficiency: effect on the musculo-venous pump, evaluated by strain gauge plethysmography. *Phlebology*. 1986;1:189–96.
503. Leon M, Volteas N, Labropoulos N, et al. The effect of elastic stockings on the elasticity of varicose veins. *Int Angiol*. 1993;12:173–177.
504. Horner J, Fernandes e Fernandes J, et al. Value of graduated compression stockings in deep venous insufficiency. *BMJ*. 1980;280:820–821.
505. Abu Own A, Shami SK, Chittenden SJ, et al. Microangiopathy of the skin and the effect of leg compression in patients with chronic venous insufficiency. *J Vasc Surg*. 1994;19:1074–1083.
506. Horakova MA, Mayer W, Partsch H. Paramètres microcirculatoires: prédiction de la tendance à la cicatrisation des ulcères des jambe. *Phlebologie*. 1996;49:461–466.
507. Leu AJ, Yanar A, Geiger M, et al. Microangiopathy in chronic venous insufficiency before and after sclerotherapy and compression treatment (results of a one year follow up study). *Phlebology*. 1993;8:99–106.
508. Stacey MC, Burnand KG, Layer GT, et al. Transcutaneous oxygen tensions in assessing the treatment of healed venous ulcers. *Br J Surg*. 1990;77:1050–1054.
509. Curri SB, Annoni F, Pabisch S, et al. Changes of cutaneous microcirculation from elasto-compression in chronic venous insufficiency. In: Davy A, Stemmer R, eds. *Phlebologie*. London, UK: John Libbey; 1989:852–854.
510. Lawrence D, Kakkar VV. Graduated, static external compression of the lower limb: a physiological assessment. *Br J Surg*. 1980;67:119–121.
511. Kristensen JK, Sindrup JH, Petersen LJ, et al. A conventional compression bandage lacks effect on subcutaneous blood flow when walking and during passive dependence in chronic venous insufficiency. *Acta Derm Venereol*. 1991;71:450–451.

512. Bollinger A, Partsch H, Wolfe JHN. *The Initial Lymphatics*. Stuttgart, Germany/New York, NY: G Thieme; 1985.
513. Allegra C, Oliva E, Bartolo M, et al. Haemodynamic modifications induced by elastic compression therapy in CVI evaluated by microlymphography. *Phlebology*. 1995;11(suppl 1):1138–1149.
514. Haid H, Lofferer O, Mostbeck A, et al. Die Lymphkinetik beim post-thrombotischen Syndrom unter Kompressionsverbänden. *Med Klin*. 1968;63:754–759.
515. Franzeck UK, Spiegel I, Fiscer M, et al. Combined physical therapy for lymphoedema evaluated by fluorescence microlymphography and lymph capillary pressure measurements. *J Vasc Res*. 1997;34:306–311.
516. Good clinical practice for trials in medicinal products in the European Community. EG-Note for guidance of the CPMP Working Party on Efficacy of Medical Products (iii/30976/88-EN, final). Brussels: European Union Publication; 1990.
517. Villavicencio JL, Pfeifer JR, Lohr JM, et al. Sclerotherapy for varicose veins: practice guidelines and sclerotherapy procedures. In: Gloviczki P, Yao JST, eds. *Handbook of Venous Disorders: Guidelines of the American Venous Forum*. London, UK: Chapman and Hall; 1996:337–354.
518. Baccaglini U. Consensus conference on sclerotherapy. *Int Angiol*. 1995; 14:239–240.
519. Baccaglini U. Document de consensus sur sclérothérapie des varices des membres inférieurs. *Phlébologie*. 1996;49:311–334.
520. Kistner RL, Eklof B, Masuda EM. Deep venous valve reconstruction. *Cardiovasc Surg*. 1995;3:129–140.
521. O' Donnell TF Jr, Mackey WC, Shepard AD, et al. Clinical, hemodynamic and anatomic follow-up of direct venous reconstruction. *Arch Surg*. 1987;122:474–482.
522. Mulliken JB, Young AE, eds. *Vascular birthmarks: Haemangiomas and Malformations*. Philadelphia, Pa: WB Saunders; 1988:114–127.
523. Lindemayr W, Lofferer O, Mostbeck A, et al. Arteriovenous shunts in primary varicosis: a critical essay. *Vasc Surg*. 1972;6:9–13.
524. Partsch H, Lofferer O, Mostbeck A. Zur Diagnostik von arteriovenösen Fisteln bei Angiodysplasien der Extremitäten. *Vasa*. 1975;4:288–295.
525. Huch Böni RA, Brunner U, Bollinger A, et al. Management of congenital angiodysplasia of the lower limb: magnetic resonance imaging and angiography versus conventional angiography. *Br J Radiol*. 1995; 68:1308–1315.
526. Nicolaides AN, Bergqvist D, Hull R. Prevention of venous thromboembolism: international consensus statement (guidelines according to scientific evidence). *Int Angiol*. 1997;16:3–38.