

# Circulation

JOURNAL OF THE AMERICAN HEART ASSOCIATION



## Chronic Venous Insufficiency

Robert T. Eberhardt and Joseph D. Raffetto

*Circulation* 2005;111;2398-2409

DOI: 10.1161/01.CIR.0000164199.72440.08

Circulation is published by the American Heart Association, 7272 Greenville Avenue, Dallas, TX 75214

Copyright © 2005 American Heart Association. All rights reserved. Print ISSN: 0009-7322. Online ISSN: 1524-4539

The online version of this article, along with updated information and services, is located on the World Wide Web at:

<http://circ.ahajournals.org/cgi/content/full/111/18/2398>

Subscriptions: Information about subscribing to *Circulation* is online at  
<http://circ.ahajournals.org/subscriptions/>

Permissions: Permissions & Rights Desk, Lippincott Williams & Wilkins, a division of Wolters Kluwer Health, 351 West Camden Street, Baltimore, MD 21202-2436. Phone: 410-528-4050. Fax: 410-528-8550. E-mail:  
[journalpermissions@lww.com](mailto:journalpermissions@lww.com)

Reprints: Information about reprints can be found online at  
<http://www.lww.com/reprints>

## Chronic Venous Insufficiency

Robert T. Eberhardt, MD; Joseph D. Raffetto, MD

Chronic venous disease is often overlooked by primary and cardiovascular care providers because of an underappreciation of the magnitude and impact of the problem. The importance of chronic venous disease is related to the number of people with the disease and the socioeconomic impact of its more severe manifestations. Unfortunately, the literature concerning the prevalence and incidence of chronic venous disease has varied greatly because of differences in the methods of evaluation, criteria for definition, and the geographic regions analyzed. The most common manifestations of chronic venous disease are dilated cutaneous veins, such as telangiectases and reticular veins, and varicose veins. The term chronic venous insufficiency (CVI) describes a condition that affects the venous system of the lower extremities with venous hypertension causing various pathologies including pain, swelling, edema, skin changes, and ulcerations. Although the term CVI is often used to exclude uncomplicated varicose veins, varicose veins have incompetent valves with increased venous pressure leading to progressive dilation and tortuosity. We will use the term CVI to represent the full spectrum of manifestations of chronic venous disease.

Varicose veins have an estimated prevalence between 5% to 30% in the adult population, with a female to male predominance of 3 to 1, although a more recent study supports a higher male prevalence.<sup>1</sup> The Edinburgh Vein Study screened 1566 subjects with duplex ultrasound for reflux finding CVI in 9.4% of men and 6.6% of women, after age adjustment, which rose significantly with age (21.2% in men >50 years old, and 12.0% in women >50 years old).<sup>2</sup> The San Valentino Vascular Screening Project found among the 30 000 subjects evaluated by clinical assessment and duplex ultrasound a prevalence of 7% for varicose veins and 0.86% for "symptomatic" CVI.<sup>3</sup> As in previous studies, CVI was more common with increasing age, but there was no significant sex difference. The rate of varicose vein development may be estimated from the Framingham Heart Study, which found an annual incidence of 2.6% in women and 1.9% in men.<sup>4</sup> Risk factors found to be associated with CVI include age, sex, a family history of varicose veins, obesity, pregnancy, phlebitis, and previous leg injury.<sup>5,6</sup> There also may be environmental or behavioral factors associated with CVI such as prolonged standing and perhaps a sitting posture at work.<sup>6,7</sup>

Varicose veins have a significant impact on healthcare resources, with millions of people seeking medical attention for their cosmetic appearance annually. Although often minimized, the cosmetic consequences may adversely affect an individual's quality of life and are associated with other manifestations.

The more serious consequences of CVI such as venous ulcers have an estimated prevalence of  $\approx 0.3\%$ , although active or healed ulcers are seen in  $\approx 1\%$  of the adult population.<sup>8</sup> It has been estimated that  $\approx 2.5$  million people have CVI in the United States, and of those,  $\approx 20\%$  develop venous ulcers.<sup>9</sup> The overall prognosis of venous ulcers is poor, with delayed healing and recurrent ulceration being common.<sup>10</sup> More than 50% of venous ulcers require prolonged therapy lasting >1 year.<sup>5</sup> The socioeconomic impact of venous ulceration is dramatic, resulting in an impaired ability to engage in social and occupational activities, thus reducing the quality of life and imposing financial constraints. Disability related to venous ulcers leads to loss of productive work hours, estimated at 2 million workdays/year, and may cause early retirement, which is found in up to 12.5% of workers with venous ulcers.<sup>11</sup> The financial burden of venous ulcer disease on the healthcare system is readily apparent: An estimated \$1 billion is spent annually on the treatment of chronic wounds in the United States, or up to 2% of the total healthcare budget in all Western countries, and recent estimates place the cost of venous ulcer care at \$3 billion annually.<sup>12,13</sup>

Given the prevalence and socioeconomic impact of chronic venous disease, an understanding of the clinical manifestations, diagnostic modalities, and therapeutic options is warranted. This article reviews the clinical aspects of CVI with a focus on the diagnostic and therapeutic options.

### Venous Pathophysiology

#### Normal Venous Anatomy and Function

To appreciate the pathophysiology of CVI, an understanding of the normal venous anatomy and function is necessary. The peripheral venous system functions as a reservoir to store blood and as a conduit to return blood to the heart. Proper functioning of the peripheral venous system depends on a series of valves and muscle pumps. Blood that enters into the lower-extremity venous system must travel against gravity

From Cardiovascular Medicine, Boston Medical Center (R.T.E.), Vascular Surgery, Boston VA Health System (J.D.R.), and Boston University School of Medicine (R.T.E., J.D.R.), Boston, Mass.

Correspondence to Robert T. Eberhardt, MD, Boston Medical Center, 88 E Newton St, C818, Boston, MA 02118. E-mail robert.eberhardt@bmc.org (*Circulation*. 2005;111:2398-2409.)

© 2005 American Heart Association, Inc.

*Circulation* is available at <http://www.circulationaha.org>

DOI: 10.1161/01.CIR.0000164199.72440.08

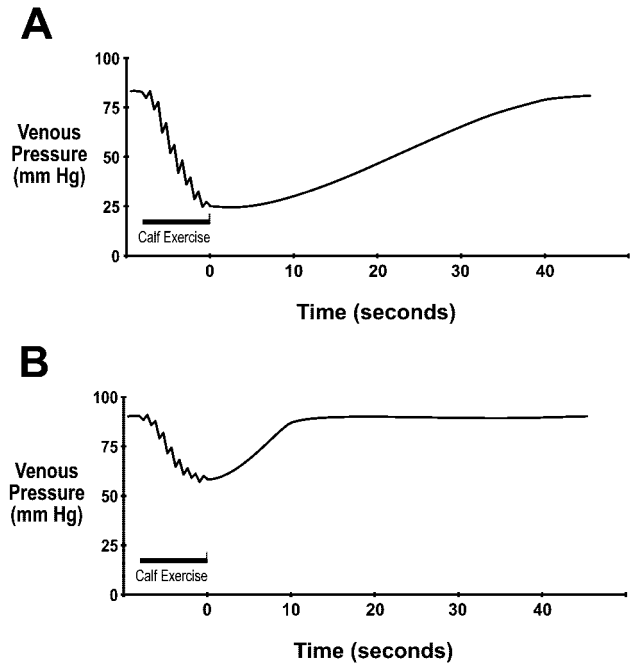
and against fluctuating thoracoabdominal pressures to return to the central circulation in a person in an erect position.

The veins of the lower extremity are divided into the superficial and deep venous system connected by a series of perforator veins.<sup>14,15</sup> The superficial venous system is located above the muscular fascial layer. It comprises an interconnecting network of veins, which serve as the primary collecting system, and several truncal superficial veins, which function as a conduit to return blood to the deep venous system. The principal named superficial veins of the lower extremity are the short (or lesser) saphenous vein, which runs from the ankle typically to join the popliteal vein at the saphenopopliteal junction, and the great saphenous vein, which runs from the ankle to join the common femoral vein at the saphenofemoral junction. Other superficial veins, including the posterior arch, lateral accessory saphenous, and vein of Giacomini, also can develop pathology leading to CVI.

The deep venous system is located below the muscular fascia and serves as collecting veins and the outflow from the extremity. The deep veins of the lower extremity consist of axial veins, which follow the course of the major arteries, and the intramuscular veins. Venous sinusoids within the leg muscles coalesce to form intramuscular venous plexi. Paired calf veins, which, corresponding to the axial arteries, merge to form a single large popliteal vein. The popliteal vein, on passing through the adductor canal, is subsequently known as the femoral (often called the superficial femoral) vein. The femoral vein is joined by the profunda femoris (or deep femoral) vein in the upper thigh to form the major outflow of the leg, the common femoral and eventually the external iliac vein. The superficial veins are connected to the deep venous system by a number of perforating veins in the thigh and leg that pass through anatomic fascial spaces.

A series of bicuspid valves are located throughout the deep and superficial veins and ensures that blood moves in the cephalad direction, preventing the return of blood toward the feet while in the upright posture.<sup>14</sup> The first of these lower-extremity valves is usually located in the common femoral vein or less commonly in the external iliac vein. The frequency of venous valves increases from the proximal to the distal leg to prevent an increase in pressure within the distal veins resulting from the effects of gravity. Perforating veins also contain one-way valves that prevent reflux of blood from the deep veins into the superficial system.

The valves function in concert with venous muscle pumps to allow the return of blood against gravity to the heart.<sup>16</sup> Contraction of the muscle pumps primarily in the calf, but also in the foot and thigh, and forces blood out of the venous plexi and up the deep venous system because of increased pressure within the fascial compartments. The valve system prevents blood from being forced distally within the deep venous system or through the perforator system into the superficial system. Immediately after ambulation, the pressure within the veins of the lower extremity is normally low (15 to 30 mm Hg) because the venous system has been emptied by the muscle pump function (Figure 1A). Relaxation of the muscle pump then allows blood to return to the



**Figure 1.** Illustrative ambulatory venous pressure measurements. (A) Normal venous pressure. The resting standing venous pressure is  $\approx 80$  to  $90$  mm Hg. The pressure drops with calf exercise to  $\approx 20$  to  $30$  mm Hg, or a  $>50\%$  decrease. The return in pressure is more gradual, with refill taking  $>20$  s. (B) Abnormal venous pressure with deep venous reflux. The drop in pressure with exercise is blunted ( $<50\%$  decrease). The return in venous pressure to the resting level is rapid because of a short refill time ( $<20$  s).

deep venous system via arterial inflow through the superficial and the distal deep venous systems. With prolonged standing, the veins slowly fill and become distended, allowing the valves to open and eventually increase pressure that is directly related to the height of the column of blood. Contraction of the muscle pump will again empty the veins and reduce venous pressure.

### Venous Pathophysiology and Dysfunction

Venous pathology develops when venous pressure is increased and return of blood is impaired through several mechanisms.<sup>17</sup> This can result from valvular incompetence of the axial deep or superficial veins, perforator valve incompetence, venous obstruction, or a combination of these. These factors are exacerbated by muscle pump dysfunction in the lower extremity. These mechanisms serve to produce venous hypertension particularly with standing or ambulation. Contributing to the macrocirculatory hemodynamic disturbances are alterations within the microcirculation.<sup>18,19</sup> Unabated venous hypertension may result in dermal changes with hyperpigmentation, subcutaneous tissue fibrosis ("lipodermatosclerosis"), and eventual ulceration.

With failure of the valves of the deep veins, normal blood volume is pumped out of the extremity, but refill occurs by both arterial inflow and pathological retrograde venous flow. The venous pressure immediately after ambulation may be slightly elevated or even normal, but veins refill quickly with the development of high venous pressure without muscle

contraction (Figure 1B). Dysfunction of the valves of the deep venous system is most often a consequence of damage from previous deep vein thrombosis (DVT).<sup>20</sup>

Dysfunction or incompetence of the valves in the superficial venous system also allows retrograde flow of blood and increased hydrostatic pressures. Valve failure may be primary the result of preexisting weakness in the vessel wall or valve leaflets, or secondary to direct injury, superficial phlebitis, or excessive venous distention resulting from hormonal effects or high pressure.<sup>17</sup> Failure of valves located at the junctions of the deep and superficial systems, most notably at the saphenofemoral and saphenopopliteal junctions, allows high pressure to enter the superficial veins. In this situation, venous dilatation and varicose veins form and propagate from the proximal junction site down the extremity.

High pressure also can enter the superficial system because of failure of the valves in the communicating perforator veins.<sup>21,22</sup> Perforator valve incompetence allows blood to flow from deep veins backward into the superficial system and the transmission of the high pressures generated by the calf muscle pump. This local high pressure can produce excessive venous dilatation and secondary failure of superficial vein valves. As a result, a cluster of dilated veins develops at this site and appears to ascend up the leg. Clinically relevant perforator vein incompetence is typically associated with reflux of the deep and/or superficial venous system.<sup>21,22</sup>

Obstruction of the deep veins may limit the outflow of blood, causing increased venous pressure with muscle contraction and secondary muscle pump dysfunction. Obstruction may occur because of an intrinsic venous process, such as previous DVT with inadequate recanalization or venous stenosis, or because of extrinsic compression, as in May-Thurner syndrome (compression of the left common iliac vein as it traverses between the right common iliac artery and the lumbosacral region). Venous outflow obstruction appears to play a more significant role in the pathogenesis of CVI and its clinical expression than previously appreciated.<sup>23</sup>

Dysfunction of the muscle pumps leads to venous blood not being effectively emptied out of the distal extremity. This rarely occurs as a "primary" disorder with neuromuscular conditions or muscle wasting syndromes; however, clinically significant muscle pump dysfunction often occurs in the setting of severe reflux or obstruction. The immediate post-ambulatory venous pressure will be nearly as high as the pressure after prolonged standing. Muscle pump dysfunction appears to be a major mechanism for the development of superficial venous incompetence and its complications such as venous ulcers.<sup>24,25</sup>

Changes in the hemodynamics of the large veins of the lower extremity are transmitted into the microcirculation and eventually result in the development of venous microangiopathy.<sup>18</sup> Features of this microangiopathy include elongation, dilation, and tortuosity of capillary beds, thickening of basement membranes with increased collagen and elastic fibers, endothelial damage with widening of interendothelial spaces, and increased pericapillary edema with "halo" formation. The abnormal capillaries with increased permeability and high venous pressure leads to the accumulation of fluid,

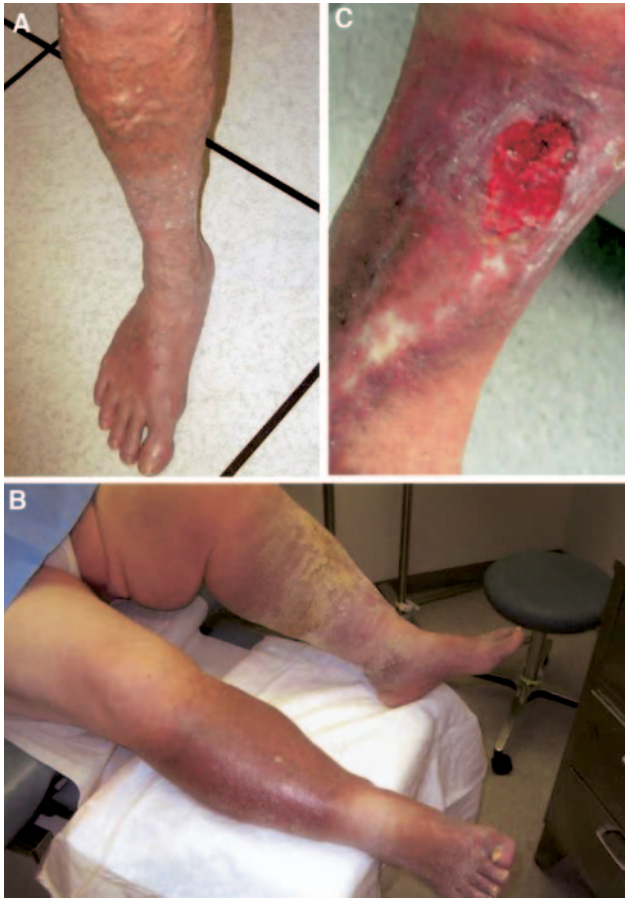macromolecules, and extravasated red blood cells into the interstitial space. In addition to changes in the blood vessels and connective tissue, alteration in the lymphatic network and nervous system may occur. Fragmentation and destruction of microlymphatics may further impair drainage from the extremity, whereas dysfunction of local nerve fibers may alter regulatory mechanisms.

Several mechanisms for the development of venous microangiopathy have been postulated, including fibrin cuff formation, growth factor trapping, and white blood cell trapping.<sup>18</sup> The fibrin cuff theory involves the accumulation of fluid containing fibrin into the pericapillary space. This cuff with impaired fibrinolysis is speculated to increase the diffusion barrier, inhibit the repair process, and maintain the inflammatory process. A related mechanism is the trapping of growth factor by fibrin and other macromolecules, making them unavailable to facilitate healing. Another theory involves the trapping of white blood cells in the capillaries or postcapillary venules. The adhesion of white blood cells with activation releases inflammatory mediators and proteolytic enzymes with endothelial damage that may increase permeability or impede flow leading to occlusion.

### Clinical Manifestations

CVI represents a spectrum of conditions ranging from simple telangiectases or reticular veins to more advanced stages such as skin fibrosis and venous ulceration. It is important to realize that the same clinical manifestations may result from the varied pathogenic mechanisms (ie, incompetent valves alone, venous obstruction alone, muscle pump dysfunction alone, or a combination). The major clinical features of CVI are dilated veins, edema, leg pain, and cutaneous changes. Varicose veins are dilated superficial veins that become progressively more tortuous and larger (Figure 2A). They are prone to develop bouts of superficial thrombophlebitis. Edema begins in the perimalleolar (or gaiter) region but ascends up the leg with dependent accumulation of fluid. The leg pain or discomfort is described as heaviness or aching after prolonged standing and relieved by elevation of the leg. Edema presumably produces the pain by increasing intracompartmental and subcutaneous volume and pressure. There also may be tenderness along varicose veins from venous distention. Obstruction of the deep venous system may lead to venous claudication, or intense leg cramping with ambulation. Cutaneous changes include skin hyperpigmentation from hemosiderin deposition and eczematous dermatitis (Figure 2B). Fibrosis may develop in the dermis and subcutaneous tissue (lipodermatosclerosis). There is an increased risk of cellulitis, leg ulceration, and delayed wound healing (Figure 2C). Long-standing CVI also may lead to the development of lymphedema, representing a combined disease process.

The manifestations of CVI may be viewed in terms of a well-established clinical classification scheme. The CEAP—Clinical, Etiology, Anatomic, Pathophysiology—classification was developed by an international consensus conference to provide a basis for uniformity in reporting, diagnosing, and treating CVI (Table 1).<sup>26</sup> The clinical classification has 7 categories (0 to 6) and is further categorized by the presence



**Figure 2.** Manifestations of CVI. A, Uncomplicated varicose veins. B, Hyperpigmentation, dermatitis, and severe edema likely resulting from combined lymphedema. C, Active and healed venous ulcerations.

or absence of symptoms. The etiologic classification is based on congenital, primary, and secondary causes of venous dysfunction. Congenital disorders are those that are present at birth, although they may be recognized later in life, including the well-recognized Klippel-Trenaunay (varicosities and venous malformations, capillary malformation, and limb hypertrophy) and Parkes-Weber (venous and lymphatic malformations, capillary malformations, and arteriovenous fistulas) syndromes.<sup>27</sup> The cause of primary venous insufficiency is uncertain, whereas secondary venous insufficiency is the result of an acquired condition. The anatomic classification describes the superficial, deep, and perforating venous systems, with multiple venous segments that may be involved. The pathophysiological classification describes the underlying mechanism resulting in CVI, including reflux, venous obstruction, or both. Validation of the CEAP classification system has often focused on the clinical classification.<sup>28</sup> The classification is a valuable tool in the objective evaluation of CVI, providing a system to standardize CVI classification, with emphasis on the manifestations, cause, and distribution of the venous disease that is widely accepted.<sup>29</sup>

There are limitations to the CEAP clinical classification, which is arbitrary and subjective with inadequate delineation of the categories. To complement the CEAP classification

**TABLE 1. CEAP Classification of Chronic Venous Disease**

Classification	Description/Definition
C, Clinical (subdivided into A for asymptomatic, S for symptomatic)	
0	No venous disease
1	Telangiectases
2	Varicose veins
3	Edema
4	Lipodermatosclerosis or hyperpigmentation
5	Healed ulcer
6	Active ulcer
E, Etiologic	
Congenital	Present since birth
Primary	Undetermined etiology
Secondary	Associated with post-thrombotic, traumatic
A, Anatomic distribution (alone or in combination)	
Superficial	Great and short saphenous veins
Deep	Cava, iliac, gonadal, femoral, profunda, popliteal, tibial, and muscular veins
Perforator	Thigh and leg perforating veins
P, Pathophysiological	
Reflux	Axial and perforating veins
Obstruction	Acute and chronic
Combination of both	Valvular dysfunction and thrombus

and further define the severity of CVI, a venous severity score was developed.<sup>30</sup> The venous severity scoring provides a numeric score based on 3 components: the venous clinical severity score, the anatomic segment disease score, and the disability score. The venous clinical severity score consists of 10 attributes (pain, varicose veins, venous edema, skin pigmentation, inflammation, induration, number of ulcers, duration of ulcers, size of ulcers, and compressive therapy) with 4 grades (absent, mild, moderate, severe). The venous anatomic segmental score assigns a numerical value to segments of the venous system in the lower extremity that account for both reflux and obstruction. The venous disability score comes from the ability to perform normal activities of daily living with or without compressive stockings. The venous severity scoring has been shown to be useful to evaluate the response to treatment.<sup>31</sup>

**Diagnosis of CVI**

The diagnosis of CVI is made via patient history and physical examination with the assistance of noninvasive testing. Invasive testing also may be used to establish the diagnosis, but it is typically reserved for assessing disease severity or when surgical intervention is being contemplated. A comprehensive overview of the methods to assess CVI may be found in a previously published consensus statement.<sup>32</sup>

**Physical Examination**

The physical examination plays an important role in guiding therapy in CVI. Inspection and palpation may reveal visual

evidence for chronic venous disease. The surface of the skin is examined for irregularities or bulges to suggest the presence of varicose veins. Hyperpigmentation, stasis dermatitis, atrophic blanche (white scarring at the site of previous ulcerations with a paucity of capillaries), or lipodermatosclerosis may be observed. The distribution of varicose veins may follow the course of the affected superficial vein, such as the great or short saphenous veins. Examination should include an evaluation of the patient in the upright posture to allow maximal distention of the veins and from multiple directions. The presence of edema and its severity are assessed. Edema is usually pitting; however, early evidence may be calf fullness or increased limb girth, so the calf muscle consistency should be assessed and measurement of the limb girth should be performed. Long-standing edema may become more resilient to palpation with "brawny" edema. Palpation also may reveal tenderness of the dilated veins. Active or healed ulcers are seen with more advanced disease. The venous ulcers usually occur in the medial supramalleolar area at the site of major perforating veins and the greatest hydrostatic pressure.

A classic tourniquet (or Trendelenberg) test may be performed at bedside to help distinguish deep from superficial reflux.<sup>33</sup> The test is performed with the patient lying down to empty the lower extremity veins. The upright posture is resumed after applying a tourniquet or using manual compression at various levels. In the presence of superficial disease the varicose veins will remain collapsed if compression is more proximal or cephalad to the point of reflux. With deep (or combined) venous insufficiency, the varicose veins will appear despite the use of the tourniquet or manual compression. Although useful to help determine the distribution of venous insufficiency, this test does not help determine the extent or severity of disease or provide information about the cause.

The use of continuous wave Doppler has often been used to assist in the bedside evaluation.<sup>34</sup> The presence and direction of flow in the veins (eg, common femoral vein) may be determined after maneuvers, such as the Valsalva maneuver or the sudden release of thigh or calf compression. Minimal signal should be detected toward the feet with these maneuvers. This technique also has been used to assess the great and short saphenous veins, although this is technically more difficult because of the lack of direct visualization. A limitation of this technique relates to the inability to insonate an individual vessel while flow is detected in any vessel within the path of the ultrasound beam. The lack of direct visualization of the vessels leaves uncertainty about the precise site of reflux.

#### **Differential Diagnosis**

There is a broad differential for the common presenting complaint in limb swelling and discomfort seen with CVI. Acute venous problems such as DVT need to be excluded. Systemic causes of edema need to be considered such as heart failure, nephrosis, liver disease, endocrine disorders, or a side effect of a medication, such as calcium channel blockers, nonsteroidal antiinflammatory agents, and oral hypoglycemic agents. Other regional considerations include a ruptured

popliteal cyst, soft tissue hematoma or mass, chronic exertional compartment syndrome, a gastrocnemius tear, or lymphedema. The use of examination findings and noninvasive testing allows for the proper diagnosis to be established.

#### **Noninvasive Testing**

##### *Venous Duplex Imaging*

Venous duplex imaging is a well-established method to diagnosis DVT. The technique also is used to confirm the diagnosis of CVI and assess its etiology and severity.<sup>35,36</sup> Venous duplex imaging combines B-mode imaging of the deep and superficial veins with pulsed Doppler assessment of flow. This provides information about the anatomic extent of disease involving the deep and superficial systems, as well as perforators. A standard venous duplex examination is performed to exclude DVT or venous obstruction. Venous compressibility complimented by flow characteristics is the key element of the examination to exclude thrombosis. The direction of flow may be assessed in a 30° reverse Trendelenberg position during provocative maneuvers, such as the Valsalva maneuver, or after augmenting flow with limb compression. The use of a cuff inflation-deflation method with rapid cuff deflation in the standing position is preferred to induce reflux.<sup>37</sup>

The presence of reflux is determined by the direction of flow because any significant flow toward the feet is suggestive of reflux. The duration of reflux is known as the reflux time (replacing the commonly used valve closure time). A reflux time of >0.5 (or 1.0) second has been used to diagnosis the presence of reflux, although a more refined definition with a variable "cutoff" based on location has been suggested.<sup>38</sup> The longer the duration of reflux or the greater the reflux time implies more severe disease. Other parameters such as the reflux velocity and even the calculated reflux volume have been used to assess the severity of reflux.<sup>39</sup> These parameters, however, provide at best a semiquantitative assessment of the severity of disease. Importantly, there is a weak correlation of the severity of disease by duplex imaging with both plethysmographic techniques and clinical manifestations.

Despite the limitation of the venous duplex reflux evaluation, it is considered the mainstay of the noninvasive evaluation of CVI. Venous duplex imaging may provide information about local valve function to construct an anatomic map of disease in terms of the systems and levels of involvement. This is often adequate information to help guide therapy, but if the contribution of the reflux to global hemodynamics is required, then further testing, such as plethysmographic techniques, may be considered.

##### *Photoplethysmography*

Photoplethysmography (PPG) may be used to establish a diagnosis of CVI.<sup>40</sup> Relative changes in blood volume in the dermis of the limb can be determined by measuring the backscatter of light emitted from a diode with a photosensor. A PPG probe is placed on the foot with maneuvers to empty the foot with calf muscle contraction. Then return of blood is detected by increased backscatter of light and the refill time may be calculated. The venous refill time is the time required

for the PPG tracing to return to 90% of the baseline after cessation of calf contraction. The measure is not quantitative, but it has been shown to correlate with invasive measurements to diagnosis CVI.<sup>41</sup> A venous refill time <18 to 20 seconds, depending on the patient's position during the study, is indicative of CVI.<sup>40,41</sup> A venous refill time >20 seconds suggests normal venous filling. The use of a tourniquet or low-pressure cuff allows for distinguishing superficial from deep venous disease. Correction of an abnormal refill time with a low-pressure thigh cuff is indicative of great saphenous vein disease. Failure to correct rapid venous refill time with a low-pressure cuff is indicative of deep venous disease. The test provides information about regional venous function, not about specific anatomic distribution. Although a shorter rapid refill time suggests more severe disease, there is a poor correlation of the severity of disease as assessed by other methods.<sup>32</sup> Refill time depends on several factors, including the volume of reflux and the vessel diameter. The technique has been used to assess emptying of the venous system during calf muscle contraction and venous outflow.<sup>32</sup> PPG may provide an assessment of the overall physiological function of the venous system, but it is most useful to determine the absence or presence of disease.

#### *Air Plethysmography*

Air plethysmography (APG) has the ability to measure each potential component of the pathophysiological mechanisms of CVI—reflux, obstruction, and muscle pump dysfunction.<sup>42,43</sup> Changes in limb volume are measured by air displacement in a cuff surrounding the calf during maneuvers to empty and fill the venous system. Venous outflow is assessed during rapid cuff deflation on an elevated limb that has a proximal venous occlusion cuff applied. The outflow fraction at 1 second (or venous outflow at 1 second expressed as a percentage of the total venous volume) is the primary parameter used to evaluate the adequacy of outflow. The limb is then placed in the dependent position to evaluate the venous filling. The rate of refill is used to determine the presence and severity of reflux. The key parameter is the venous filling index, which is calculated by measuring 90% of the venous volume and dividing this by the time required to fill 90% of the venous volume after resuming an upright position. A normal venous filling index is <2 mL/s, whereas higher levels (>4 to 7 mL/s) have been found to correlate with the severity of CVI.<sup>44,45</sup> The venous filling index may be the best parameter in the detection of abnormal reflux, with a sensitivity of 70% to 80% and positive predictive value of 99%.<sup>43</sup> The ability of the calf muscle pump to eject blood is determined after a single and 10 repetitive contractions during toe raises. The volume of blood ejected with 1 tiptoe maneuver divided by the venous volume is the so-called ejection fraction. Complications of CVI, such as ulceration, have been shown to correlate with the severity of reflux assessed with the venous filling index and ejection capacity.<sup>32,42,44</sup> This technique provides quantitative information about several aspects of global venous function. It may be used in the selection of intervention and assessment of the response to intervention.<sup>46,47</sup>

#### *Other Techniques*

Other techniques such as strain gauge plethysmography and foot volumetry also may be used. Both techniques provide

physiological information about global venous function and may correlate better with the clinical severity than does duplex imaging.<sup>48</sup>

#### *Invasive Testing*

##### *Phlebography*

Phlebography or venography may be either ascending or descending.<sup>49</sup> Ascending phlebography involves the injection of contrast in the dorsum of the foot with visualization of contrast traveling up the lower extremity in the deep venous system. Although ascending phlebography is considered the gold standard to determine the patency of veins, it has been largely replaced by noninvasive imaging. It does provide details of venous anatomy that may be useful with surgical interventions and can help to distinguish primary from secondary disease. Descending phlebography involves proximal injection of contrast in a semivertical posture on a tilt table with the use of the Valsalva maneuver. It is most useful to identify reflux in the common femoral vein and at the saphenofemoral junction, but it may be used to evaluate other locations. A grading scheme has been developed based on the anatomic extent of reflux. This modality has been largely replaced by duplex scanning. It is now performed if deep venous reconstruction is being contemplated or with an inconclusive duplex scan before other venous surgery.

##### *Ambulatory Venous Pressure*

Ambulatory venous pressure (AVP) monitoring is the hemodynamic gold standard in assessing CVI.<sup>50,51</sup> The technique involves insertion of a needle into the pedal vein with connection to a pressure transducer. The pressure is determined at rest and after exercise is performed, usually in the form of toe raises. The pressure also is monitored before and after the placement of an ankle cuff to help distinguish deep from superficial reflux. AVP has been shown to be valuable in assessing the severity and clinical outcomes in CVI.<sup>52</sup> The mean ambulatory venous pressure (normal range of 20 to 30 mm Hg) and refill time (normal range of 18 to 20 seconds) are the most useful measurements. AVP provides information on the global competence of the venous system; however, there is concern about the failure of pressure to accurately reflect the pressure within the deep system.<sup>53</sup> Because of the invasive nature and alternative diagnostic modalities, AVP seldom is used in clinical practice. Attempts to determine AVP by noninvasive means have been evaluated in small studies and are not widely used.<sup>54</sup>

#### *Selection of Studies*

The purpose of the testing needs to be considered upon selecting a diagnostic modality. All of the noninvasive modalities may be performed to establish a diagnosis CVI (Table 2). The modality that is most commonly used within the vascular laboratory performing the testing is typically the most appropriate for this purpose. Further information regarding the anatomic site of disease and its hemodynamic importance is often required for the treatment of CVI, however. The anatomic site of reflux, which is required to plan an intervention, is best provided by venous duplex reflux evaluation. If quantitative information is required to assess the severity of

**TABLE 2. Relative Value of Noninvasive Testing Modalities in CVI Based on Clinical Indication**

	Duplex	APG	PPG
To establish a diagnosis	+++	++	+++
To assess severity	+/-	+++	-
To determine anatomy	+++	-	-
To determine hemodynamic significance	-	+++	-

disease to guide therapy and monitor the response to therapy, then APG is appropriate.

## Treatment of CVI

### Conservative Treatment

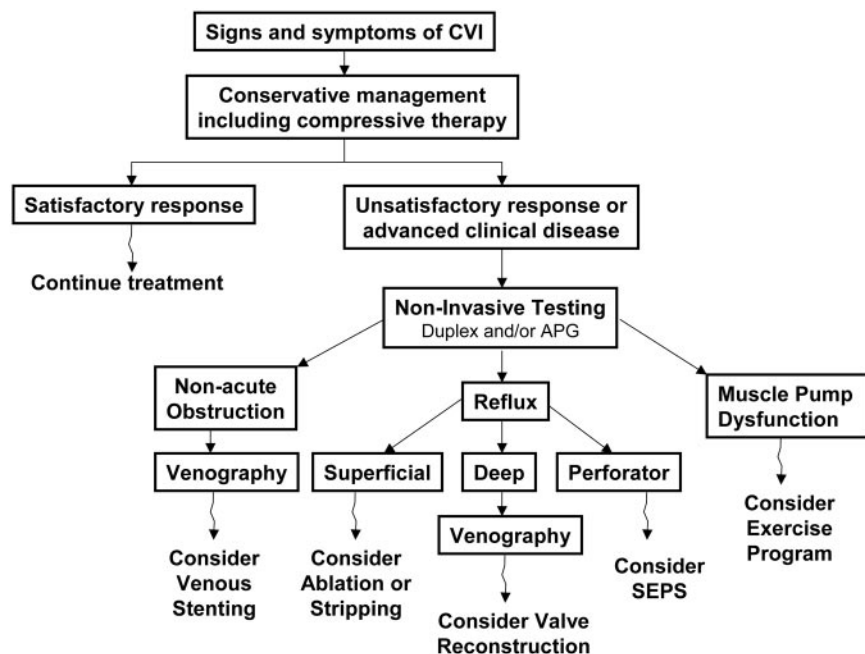
The initial treatment of CVI involves conservative measures to reduce symptoms and help prevent the development of secondary complications and the progression of disease. Behavioral measures such as elevating the legs to minimize edema and reducing intraabdominal pressure should be advocated. The use of compressive stockings is the mainstay of conservative treatment and described in more detail below. If conservative measures fail or provide an unsatisfactory response, then further treatment should be considered based on anatomic and pathophysiological features (Figure 3).

Regarding the treatment of CVI, the practitioner should be able to recognize the manifestations of CVI and use confirmatory testing such as venous duplex reflux studies and perhaps air plethysmography. Specific treatment is based on severity of disease, with CEAP clinical classes 4 to 6 often requiring invasive treatment. Referral to a vascular specialist should be made for patients with CEAP classes 4 to 6 (and probably for CEAP class 3 with extensive edema). These patients with uncorrected advanced CVI are at risk for ulceration, recurrent ulceration, and nonhealing venous ulcers with progressive infection and lymphedema.

### Compressive Leg Garments

A preliminary therapeutic consideration for all CEAP clinical classes of CVI is compression therapy. The objective is to provide graded external compression to the leg and oppose the hydrostatic forces of venous hypertension. A number of compression garments are available including graded elastic compressive stockings, paste gauze boots, layered bandaging, and adjustable layered compression garments. The use of graded elastic compressive stockings (with 20 to 50 mm Hg of tension) is well established in the treatment of CVI. Treatment with 30 to 40 mm Hg compression stockings results in significant improvement in pain, swelling, skin pigmentation, activity, and well-being if compliance of 70% to 80% is achieved.<sup>55</sup> In patients with venous ulcers, graded compression stockings and other compressive bandaging modalities are effective in both healing and preventing recurrences of ulceration. With a structured regimen of compression therapy 93% of patients with venous ulcers can achieve complete healing at a mean of 5.3 months.<sup>56</sup> Several studies have investigated the hemodynamic benefits of compression therapy in patients with CVI. Compression stockings have been shown to reduce the residual volume fraction, which is an indicator of improving the calf muscle pump function, and to reduce reflux in vein segments.<sup>57,58</sup>

The prescription for elastic compression stockings in CVI includes information about the tension and length. The tension is based on the clinical severity, with 20 to 30 mm Hg for CEAP classes 2 to 3, 30 to 40 mm Hg for CEAP classes 4 to 6, and 40 to 50 mm Hg for recurrent ulcers. The most common length is knee-length stockings because patient adherence is greater and symptom relief is adequate. The use of thigh- or waist-high stockings may be necessary in patients with edema extending above the knee, but these stockings are more difficult to use. Proper fitting of the stockings also requires diameter measure-



**Figure 3.** A simplified overview for the diagnosis and treatment of CVI based on pathophysiological mechanisms. Multiple pathophysiological mechanisms may contribute to CVI within the same patient and require a combination of treatment options.

ments of the extremity; this is most often performed at the medical supply facility. Stockings need to be changed every 6 to 9 months if worn daily with an alternate pair to avoid loss of the tension that the stockings exert.

#### *Wound and Skin Care*

Because progressive CVI may lead to compromised skin integrity, it is important to keep the affected area well moisturized to reduce the risk of skin breakdown and possibility of infection. The development of stasis dermatitis needs to be treated with a topical steroid. With venous ulcers, bacterial overgrowth control and aggressive wound care are required to minimize infectious complications. A variety of hydrocolloids and foam dressings are available to control wound fluid drainage and resultant maceration of the adjacent skin.<sup>59</sup> In the presence of an infected ulcer bed, silver-impregnated dressings have been effective in controlling infection and restoring tissue integrity.<sup>60,61</sup>

#### *Pharmacological Therapy*

Four groups of drugs have been evaluated in the treatment of CVI including coumarins ( $\alpha$ -benzopyrones), flavonoids ( $\gamma$ -benzopyrones), saponosides (horse chestnut extracts), and other plant extracts. These drugs have venoactive properties and are widely used in Europe but are not approved for use in the United States. The principle for the use of venoactive drugs in CVI is to improve venous tone and capillary permeability, although a precise mechanism of action of these drugs is not known. It is thought that the flavonoids affect leukocytes and the endothelium by modifying the degree of inflammation and reducing edema. A micronized purified flavonoid fraction, Daflon, has been shown to reduce edema-related symptoms as either primary treatment or in conjunction with surgical therapy.<sup>62</sup> A trial of 231 patients with CVI found a combination of coumarin and troxerutin (a flavonoid) with compression garments given for 12 weeks resulted in less edema and pain as compared with placebo.<sup>63</sup> Horse chestnut seed extract has been found to be as effective as compression stockings in the short-term at reducing leg edema and pain from CVI, but the long-term safety and efficacy has not been established.<sup>64,65</sup>

Other agents have been used in the treatment of advanced venous disease with ulceration. Several trials have suggested that pentoxifylline may improve venous ulcer healing rates, although the magnitude of the effect appears to be small and its role in patient management is unclear.<sup>66,67</sup> Although the use of other agents such as aspirin and platelet-derived growth factor in promoting the healing or preventing the recurrence of venous ulceration has been reported, there have been no large randomized studies. It also should be mentioned that there are no data to support the use of aspirin in the prevention of thromboembolic events in CVI.

#### *Exercise*

Abnormalities in the calf and foot muscle pump functions play a significant role in the pathophysiology of CVI. Graded exercise programs have been used in an effort to rehabilitate the muscle pump and improve the symptoms of CVI. In a

small controlled study, 31 patients with CEAP class 4 to 6 CVI were randomized to structured calf muscle exercise or routine daily activities. Venous hemodynamics was assessed with duplex ultrasound and air plethysmography, and muscle strength was assessed with a dynamometer. After 6 months, patients receiving the calf muscle exercise regimen had normalized their calf muscle pump function parameters but experienced no change in the amount of reflux or severity scores. Padberg et al concluded that structured exercise to reestablish calf muscle pump function in CVI may prove beneficial as a supplemental therapy to medical and surgical treatment in advanced disease.<sup>68</sup>

#### *Interventional Treatment*

##### *Sclerotherapy*

Venous sclerotherapy is a treatment modality for obliterating telangiectases, varicose veins, and venous segments with reflux. Sclerotherapy may be used as a primary treatment or in conjunction with surgical procedures in the correction of CVI. Sclerotherapy is indicated for a variety of conditions including spider veins (<1 mm), venous lakes, varicose veins of 1 to 4 mm in diameter, bleeding varicosities, and small cavernous hemangiomas (vascular malformation). There are a number of sclerosing agents including hypertonic solution of sodium chloride (23.4%), detergents such as sodium tetradecyl sulfate, polidocanol, and sodium morrhuate, and other compounds such as sodium iodide and chromated glycerin. In the United States, sodium tetradecyl sulfate and sodium morrhuate are approved for treating varicosities. In general, for smaller diameter veins, the sclerosing agent needs to be diluted to avoid tissue inflammation and tissue necrosis. Sclerosing agents such as polidocanol have been shown to be superior to normal saline in both obliterating incompetent varicose veins and improving venous hemodynamics at 12 weeks.<sup>69</sup> In Europe, sclerotherapy with polidocanol foam with duplex ultrasound guidance has become standard in the treatment of intracutaneous telangiectasies, subcutaneous varicose veins, transfascial perforating veins, and venous malformations.<sup>70</sup> This efficient method of sclerosing is not yet approved in the United States. A common complication of sclerotherapy is hyperpigmentation of the surrounding skin from hemosiderin degradation. Attempts to minimize complications of sclerotherapy have been undertaken with microthrombectomy with multiple small incisions directly over the thrombosed varicosity to extrude the thrombus. A randomized multicenter study found that microthrombectomy 1 to 3 weeks after the injection of small varicose veins ( $\leq 1$  mm) resulted in less hyperpigmentation, and in varicose veins up to 3 mm, it resulted in less pain and inflammation.<sup>71</sup>

##### *Ablative Therapy With Endovenous Radiofrequency and Laser*

A recent advance in venous ablative surgery is the use of thermal energy in the form of radiofrequency or laser to obliterate veins. This technique is frequently used for great saphenous vein reflux as an alternative to stripping. The heat generated causes a local thermal injury to the vein wall

leading to thrombosis and eventual fibrosis. With radiofrequency ablation of the great saphenous vein, there is complete obliteration in 85% after 2 years with recanalization in  $\approx$ 11%; however, 90% of patients treated with radiofrequency ablation are free from saphenous vein reflux and 95% of patients report satisfaction and improvement of symptoms, regardless of the technical success.<sup>72</sup> Although radiofrequency ablation is less invasive than surgical stripping, potential complications include saphenous nerve injury, mandating only treating a specific segment of the great saphenous vein, and DVT in up to 16% of limbs, requiring the use of duplex ultrasound surveillance.<sup>73</sup> Laser treatment with either an 810-nm or a 940-nm diode has provided excellent results; saphenous vein obliteration occurred in 93% at 2 years and there was no case of DVT.<sup>74</sup> Both radiofrequency and laser treatment are performed with tumescent anesthesia to prevent skin burns and reduce pain with earlier return to normal activities. Although there have been no randomized trials comparing the techniques, the techniques are associated with lower morbidity than is traditional venous surgery.

#### *Endovascular Therapy*

Endovascular therapy in the treatment of CVI has become increasingly important to restore outflow of the venous system and provide relief of obstruction. Approximately 10% to 30% of patients with severe CVI can be diagnosed with a significant abnormality in venous outflow involving iliac vein segments that contributes to persistent symptoms. Before endovascular therapy, iliac vein stenosis and obstruction causing CVI was treated with surgical procedures such as cross-femoral venous bypass or iliac vein reconstructions with prosthetic materials.<sup>75</sup> Because of the success of venous stenting, surgical venous bypass is infrequently performed. In a large single-center series of 429 patients with CVI and evidence of outflow obstruction, iliac vein stenting resulted in clinical improvement: 50% of patients were completely relieved of pain and 33% experienced complete resolution of edema.<sup>76</sup> Furthermore, 55% of patients with venous ulcers experienced complete healing of their ulcer.<sup>76</sup> Patency of iliac vein stents appears good, with primary patency of 75% at 3 years. Close follow-up is mandatory to ensure that stent patency is maintained. Also mandatory is to intervene early in patients with recurrent symptoms that may indicate in-stent restenosis, which occurs in  $\approx$ 23% of patients.<sup>77</sup>

#### *Surgical Treatment*

In severe forms of CVI, venous ulcers may require treatment for as long as 6 months before complete healing is achieved, and recurrence is frequent especially when compression therapy is not maintained. In CVI that is refractory to medical and less-invasive therapy, surgical options should be considered to complement compressive stockings, including patients who have persistent discomfort with disability, or venous ulcers that do not heal despite maximal medical efforts. Invasive and surgical options also may be considered in patients who are unable to comply with compression therapy or experience recurrent varicose veins.

#### *Ligation and Stripping and Venous Phlebectomy*

Removing the saphenous vein with high ligation of the saphenofemoral junction is considered durable and the standard for many patients with CVI.<sup>78</sup> In addition, large venous varicose clusters that communicate with the incompetent saphenous vein can be avulsed at the same setting by a technique called stab phlebectomy. There is also a newer technique of transilluminated power phlebectomy (or TriVex) to remove clusters of varicosities with fewer incisions and a decrease in operation time.<sup>79</sup> The ligation and stripping of the great saphenous vein can be applied to all CEAP clinical classes 2 to 6 with superficial venous reflux and have been shown to result in significant improvements in venous hemodynamics, possibly eliminate concomitant deep venous reflux, provide symptomatic relief of advanced stages of CVI, and assist in ulcer healing.<sup>80,81</sup> In a study evaluating 500 patients with venous ulcer and reflux of superficial and deep venous systems, randomization to surgery (only to the superficial venous segments) plus compression demonstrated a significant reduction in ulcer recurrence at 12 months as compared with compression alone (12% versus 28%).<sup>82</sup> This finding supports the additional benefit of correcting the incompetent superficial venous system on prevention of ulcer recurrence.

#### *Subfascial Endoscopic Perforator Surgery*

The importance of the incompetent perforator vein to the manifestations of CVI and its more advanced forms has been appreciated for many years. A surgical principle has been to ligate perforator veins that may contribute to the focal high pressure within the superficial veins with advanced CVI. This may present difficulties with traditional surgical techniques because of the preexisting tissue damage in the affected area. Subfascial endoscopic perforator surgery (SEPS), however, provides a means to ligate incompetent perforator veins by gaining access from a remote site on the leg that is away from the area with lipodermatosclerosis or ulcers. A multicenter study involving 148 SEPS procedures in patients with active and healed venous ulcers demonstrated accumulative ulcer healing of 88% at 1 year and an ulcer recurrence of 28% at 2 years.<sup>83</sup> SEPS also can be used in conjunction with superficial vein ablation with 91% ulcer healing at a mean of 2.9 months, and is accompanied by a significant improvement in the clinical severity and venous disability scores.<sup>84</sup> In a large study evaluating 832 patients with CEAP clinical classes 4 to 6 for 9 years, 55% of patients underwent both SEPS and ligation and stripping of the superficial venous segments. In this group, 92% of ulcers healed overall with only 4% recurrence rates, 3% nonfatal complication rate, and a significant improvement in venous hemodynamics.<sup>85</sup> This study underscores the importance of surgical interruption of incompetent superficial and perforator veins in patients with advanced CVI.

#### *Valve Reconstruction*

Venous valve injury or dysfunction may contribute to the development and progression of CVI. Venous valve reconstruction of the deep vein valves has been performed in selected patients with advanced CVI who have recurrent ulceration with severe and disabling symptoms. An open

technique for repairing the femoral vein valve that renders the valve leaflets competent has been described.<sup>86</sup> This technique of open valvuloplasty has been refined, and closed techniques for venous repair developed with transcommissural valvuloplasty.<sup>87</sup> Venous valvuloplasty has been shown to provide 59% competency and 63% ulcer-free recurrence at 30 months. Complications from valvuloplasty include bleeding because patients need to remain anticoagulated, DVT, pulmonary embolism, ulcer recurrence, and wound infections. The technique is not routinely performed and is considered in selected patients. Other procedures for reconstructing non-functioning venous valves resulting from post-thrombotic valve destruction (not amenable to valvuloplasty) include transposition of the profunda femoris vein or saphenous vein valve and axillary vein valve transplantation to the popliteal or femoral vein segments. Cryopreserved vein valve allografts also have been used; however, early thrombosis, poor patency and competency, and a high patient morbidity have precluded their use as a primary intervention.<sup>88</sup>

### Summary

Chronic venous disease is a common problem that has a significant impact on afflicted individuals and the health-care system. Normal venous function requires the axial veins with a series of venous valves, perforating veins to allow communication of the superficial to the deep venous system, and the venous muscle pumps. Dysfunction of any of the normal structures may lead to venous hypertension and the development of CVI. There is a spectrum of manifestations of CVI with an emphasis on more serious consequences such as venous ulceration. There are a number of noninvasive and invasive techniques that assist in diagnosis and treatment. The most commonly used technique is the use of venous duplex reflux evaluation to confirm the diagnosis and provide anatomic detail. The use of air plethysmography often is used to assist in assessing the severity of disease. The treatment of CVI is based on the severity of disease and guided by anatomic and pathophysiological considerations. Compressive garments have been a mainstay in treatment and should be included in the treatment of CVI. Traditional surgical techniques and newer interventional methods often are reserved for unsatisfactory response to conservative measures, although the earlier use of techniques such as venous ablation is considered.

### References

- Evans CJ, Fowkes FG, Ruckley CV, Lee AJ. Prevalence of varicose veins and chronic venous insufficiency in men and women in the general population: Edinburgh Vein Study. *J Epidemiol Community Health.* 1999;53:149–153.
- Ruckley CV, Evans CJ, Allan PL, Lee AJ, Fowkes FG. Chronic venous insufficiency: clinical and duplex correlations. The Edinburgh Vein Study of venous disorders in the general population. *J Vasc Surg.* 2002;36:520–525.
- Casaroni MR, Belcaro G, Nicolaides AN, Geroulakos G, Griffin M, Incandela L, De SM, Sabetai M, Geroulakos G, Agus G, Bavera P, Ippolito E, Leng G, Di RA, Cazaubon M, Vasdekis S, Christopoulos D, Veller M. Real epidemiology of varicose veins and chronic venous disease: the San Valentino Vascular Screening Project. *Angiology.* 2002; 53:119–130.
- Brand FN, Dannenberg AL, Abbott RD, Kannel WB. The epidemiology of varicose veins: the Framingham Study. *Am J Prev Med.* 1988;4: 96–101.
- Scott TE, LaMorte WW, Gorin DR, Menzoian JO. Risk factors for chronic venous insufficiency: a dual case-control study. *J Vasc Surg.* 1995;22:622–628.
- Jawien A. The influence of environmental factors in chronic venous insufficiency. *Angiology.* 2003;54:S19–S31.
- Lacroix P, Aboyans V, Preux PM, Houles MB, Laskar M. Epidemiology of venous insufficiency in an occupational population. *Int Angiol.* 2003; 27:172–176.
- Fowkes FG, Evans CJ, Lee AJ. Prevalence and risk factors for chronic venous insufficiency. *Angiology.* 2001;52:S5–S15.
- Rhodes JM, Gloviczki P, Canton LG, Rooke T, Lewis BD, Lindsey JR. Factors affecting clinical outcome following endoscopic perforator vein ablation. *Am J Surg.* 1998;176:162–167.
- Callam MJ, Harper DR, Dale JJ, Ruckley CV. Chronic ulcer of the leg: clinical history. *BMJ.* 1987;294:1389–1391.
- DaSilva A, Navarro MF, Batalheiro J. The importance of chronic venous insufficiency: various preliminary data on its medico-social consequences. *Phlebologie.* 1992;45:439–443.
- Laing W. *Chronic Venous Diseases of the Leg.* London, UK: Office of Health Economics; 1992:1–44.
- Pierce GF, Mustoe TA. Pharmacologic enhancement of wound healing. *Annu Rev Med.* 1995;46:467–481.
- Mózes G, Carmichael SW, Gloviczki P. Development and anatomy of the venous system. In Gloviczki P, Yao JS, eds. *Handbook of Venous Disorders.* 2nd ed. New York, NY: Arnold; 2001:11–24.
- Caggiati A, Bergan JJ, Gloviczki P, Jantet G, Wendell-Smith CP, Partsch H; International Interdisciplinary Consensus Committee on Venous Anatomical Terminology. Nomenclature of the veins of the lower limbs: an international interdisciplinary consensus statement. *J Vasc Surg.* 2002; 36:416–422.
- Padberg F. The physiology and hemodynamics of the normal venous circulation. In Gloviczki P, Yao JS, eds. *Handbook of Venous Disorders.* 2nd ed. New York, NY: Arnold; 2001:25–35.
- Burnand KG. The physiology and hemodynamics of chronic venous insufficiency of the lower limb. In Gloviczki P, Yao JS, eds. *Handbook of Venous Disorders.* 2nd ed. New York, NY: Arnold; 2001: 49–57.
- Pappas PJ, Durán WN, Hobson RW. Pathology and cellular physiology of chronic venous insufficiency. In Gloviczki P, Yao JS, eds. *Handbook of Venous Disorders.* 2nd ed. New York, NY: Arnold; 2001:58–67.
- Gschwandtner ME, Ehringer H. Microcirculation in chronic venous insufficiency. *Vasc Med.* 2001;6:169–179.
- Kahn SR, Ginsberg JS. Relationship between deep venous thrombosis and the postthrombotic syndrome. *Arch Intern Med.* 2004;164:17–26.
- Delis KT, Husmann M, Kalodiki E, Wolfe JH, Nicolaides AN. In situ hemodynamics of perforating veins in chronic venous insufficiency. *J Vasc Surg.* 2001;33:773–782.
- Labropoulos N, Mansour MA, Kang SS, Gloviczki P, Baker WH. New insight into perforator vein incompetence. *Euro J Vasc Surg.* 1999;18: 228–234.
- Neglén P, Thrasher TL, Raju S. Venous outflow obstruction: an underestimated contributor to chronic venous disease. *J Vasc Surg.* 2003;38: 879–885.
- Araki CT, Back TL, Padberg FT, Thompson PN, Jamil Z, Lee BC, Duran WN, Hobson RW. The significance of calf muscle pump function in venous ulceration. *J Vasc Surg.* 1994;20:872–877.
- Christopoulos D, Nicolaides AN, Cook A, Irvine A, Galloway JM, Wilkinson A. Pathogenesis of venous ulceration in relation to the muscle pump function. *Surgery.* 1989;106:829–835.
- Porter JM, Moneta GL. Reporting standards in venous disease: an update. International Consensus Committee on Chronic Venous Disease. *J Vasc Surg.* 1995;21:635–645.
- Noel AA, Gloviczki P, Cherry KJ, Rooke TW, Stanson AW, Driscoll DJ. Surgical treatment of venous malformations in Klippel-Trenaunay syndrome. *J Vasc Surg.* 2000;32:840–847.
- Carpentier PH, Cornu-Thenard A, Uhl JF, Partsch H, Antignani PL; Societe Francaise de Medecine Vasculaire; European Working Group on the Clinical Characterization of Venous Disorders. Appraisal of the information content of the C classes of CEAP clinical classification of chronic venous disorders: a multicenter evaluation of 872 patients. *J Vasc Surg.* 2003;37:827–833.

29. Scuderi A, Raskin B, Al Assal F, Scuderi P, Scuderi MA, Rivas CE, Costa DH, Bruginski CG, Morissugui AN. The incidence of disease in Brazil based on CEAP classification. *Int Angiol*. 2002;21:316–321.
30. Rutherford RB, Padberg FT, Comerota AJ, Kistner RL, Meissner MH, Moneta GL. Venous severity scoring: an adjunct to venous outcome assessment. *J Vasc Surg*. 2000;31:1307–1312.
31. Kakkos SK, Rivera MA, Matsagas MI, Lazarides MK, Robless P, Belcario G, Geroulakos G. Validation of the new venous severity scoring system in varicose vein surgery. *J Vasc Surg*. 2003;38:224–228.
32. Nicolaides AN. Investigation of chronic venous insufficiency: a consensus statement. *Circulation*. 2000;102:e126–e163.
33. Bradbury A, Ruckley CV. Clinical assessment of patients with venous disease. In Gloviczki P, Yao JS, eds. *Handbook of Venous Disorders*. 2nd ed. New York, NY: Arnold; 2001:71–83.
34. Folsie R, Alexander RH. Directional flow detection for the localizing venous valvular incompetence. *Surgery*. 1970;67:114–121.
35. Mattos MA, Sumner DS. Direct noninvasive tests (duplex scan) for the evaluation of chronic venous obstruction and valvular incompetence. In Gloviczki P, Yao JS, eds. *Handbook of Venous Disorders*. 2nd ed. New York, NY: Arnold; 2001:120–131.
36. Marston WA, PPG, APG, duplex: which noninvasive tests are most appropriate for the management of patients with chronic venous insufficiency? *Semin Vasc Surg*. 2002;15:13–20.
37. Markel A, Meissner MH, Manzo RA, Bergelin RO, Strandness DE. A comparison of the cuff deflation method with Valsalva's maneuver and limb compression in detecting venous valvular reflux. *Arch Surg*. 1994;129:701–705.
38. Labropoulos N, Tiongsong J, Pryor L, Tassiopoulos AK, Kang SS, Ashraf Mansour M, Baker WH. Definition of venous reflux in the lower-extremity veins. *J Vasc Surg*. 2003;38:793–798.
39. Neglen P, Egger JF, Olivier J, Raju S. Hemodynamic and clinical impact of ultrasound-derived venous reflux parameters. *J Vasc Surg*. 2004;40:303–310.
40. Nicolaides AN, Miles C. Photoplethysmography in the assessment of venous insufficiency. *J Vasc Surg*. 1987;5:405–412.
41. Abramowitz HB, Queral LA, Finn WR, Nora PF Jr, Peterson LK, Bergan JJ, Yao JS. The use of photoplethysmography in the assessment of venous insufficiency: a comparison to venous pressure measurements. *Surgery*. 1979;86:434–441.
42. Christopoulos D, Nicolaides AN, Szendro G. Venous reflux: quantification and correlation with clinical severity. *Br J Surg*. 1988;75:352–356.
43. Criado E, Farber MA, Marston WA, Daniel PF, Burnham CB, Keagy BA. The role of air plethysmography in the diagnosis of chronic venous insufficiency. *J Vasc Surg*. 1998;27:660–670.
44. Harada R, Katz M, Comerota A. A non-invasive screening test to detect "critical" deep venous reflux. *J Vasc Surg*. 1995;22:532–537.
45. Criado E, Daniel PF, Marston W, Mansfield DI, Keagy BA. Physiologic variation in lower extremity venous valvular function. *Ann Vasc Surg*. 1995;9:102–108.
46. Gillespie DL, Cordts PR, Hartono C, Woodson J, Obi-Tabot E, LaMorte WW, Menzoian JO. The role of air plethysmography in monitoring results of venous surgery. *J Vasc Surg*. 1992;16:674–678.
47. Owens LV, Farber MA, Young ML. The value of air plethysmography in predicting clinical outcome after surgical treatment of chronic venous insufficiency. *J Vasc Surg*. 2000;32:961–968.
48. Danielsson G, Norgren L, Jungbeck C, Peterson K. Global venous function correlates better than duplex derived reflux to clinical class in the evaluation of chronic venous disease. *Int Angiol*. 2003;22:177–181.
49. Kamida CB, Kistner RL, Eklof B, Masuda EM. Lower extremity ascending and descending venography. In Gloviczki P, Yao JS, eds. *Handbook of Venous Disorders*. 2nd ed. New York, NY: Arnold; 2001:132–139.
50. Masuda EM, Arfvidsson B, Eklof B, Kistner RL. Direct venous pressure: role in the assessment of venous disease. In Gloviczki P, Yao JS, eds. *Handbook of Venous Disorders*. 2nd ed. New York, NY: Arnold; 2001:140–145.
51. Nicolaides AN, Zukowski AJ. The value of dynamic venous pressure measurements. *World J Surg*. 1986;10:919–924.
52. Nicolaides AN, Hussein MK, Szendro G, Christopoulos D, Vasdekis S, Clarke H. The relation of venous ulceration with ambulatory venous pressure measurements. *J Vasc Surg*. 1993;17:414–419.
53. Neglen P, Raju S. Ambulatory venous pressure revisited. *J Vasc Surg*. 2000;31:1206–1213.
54. Fronck A, Kim R, Curran B. Non-invasively determined ambulatory venous pressure. *Vasc Med*. 2000;5:213–216.
55. Motykie GD, Caprini JA, Arcelus JI, Reyna JJ, Overom E, Mokhtee D. Evaluation of therapeutic compression stockings in the treatment of chronic venous insufficiency. *Dermatol Surg*. 1999;25:116–120.
56. Mayberry JC, Moneta GL, Taylor LM, Porter JM. Fifteen-year results of ambulatory compression therapy for chronic venous ulcers. *Surgery*. 1991;109:575–581.
57. Ibegbuna V, Delis KT, Nicolaides AN, Aina O. Effect of elastic compression stockings on venous hemodynamics during walking. *J Vasc Surg*. 2003;37:420–425.
58. Zajkowski PJ, Proctor MC, Wakefield TW, Bloom J, Blessing B, Greenfield LJ. Compression stockings and venous function. *Arch Surg*. 2002;137:1064–1068.
59. Karlsmark T, Agerslev RH, Bendz SH, Larsen JR, Roed-Petersen J, Andersen KE. Clinical performance of a new silver dressing, Contreet Foam, for chronic exuding venous leg ulcers. *J Wound Care*. 2003;12:351–354.
60. Jones SA, Bowler PG, Walker M, Parsons D. Controlling wound bioburden with a novel silver-containing Hydrofiber dressing. *Wound Repair Regen*. 2004;12:288–294.
61. Colletta V, Dioguardi D, Di Lonardo A, Maggio G, Torasso F. A trial to assess the efficacy and tolerability of Hyalofill-F in non-healing venous leg ulcers. *J Wound Care*. 2003;12:357–360.
62. Nicolaides AN. From symptoms to leg edema: efficacy of Daflon 500 mg. *Angiology*. 2003;54:S33–S44.
63. Vanscheidt W, Rabe E, Naser-Hijazi B, Ramelet AA, Partsch H, Diehm C, Schultz-Ehrenburg U, Spengel F, Wirsching M, Gotz V, Schnitker J, Henneicke-von Zepelin HH. The efficacy and safety of coumarin-troloxerutin-combination (SB-LOT) in patients with chronic venous insufficiency: a double blind placebo-controlled randomized study. *Vasa*. 2002;31:185–190.
64. Siebert U, Brach M, Sroczynski G, Berla K. Efficacy, routine effectiveness, and safety of horsechestnut seed extract in the treatment of chronic venous insufficiency. A meta-analysis of randomized controlled trials and large observational studies. *Int Angiol*. 2002;21:305–315.
65. Pittler MH, Ernst E. Horse chestnut seed extract for chronic venous insufficiency. *Cochrane Database Syst Rev*. 2004;CD003230.
66. Colgan M-P, Dormandy JA, Jones PW, Schraibman IG, Shanik DG, Young RAL. Oxpentifylline treatment venous ulcers of the leg. *BMJ*. 1990;300:972–975.
67. Dale JJ, Ruckley CV, Harper DR, Gibson B, Nelson EA, Prescott RJ. A randomised double-blind placebo controlled trial of oxpentifylline in the treatment of venous leg ulcers. *Phlebology*. 1995;Suppl 1:917–918.
68. Padberg FT, Johnston MV, Sisto SA. Structured exercise improves calf muscle pump function in chronic venous insufficiency: a randomized trial. *J Vasc Surg*. 2004;39:79–87.
69. Kahle B, Leng K. Efficacy of sclerotherapy in varicose veins: prospective, blinded, placebo-controlled study. *Dermatol Surg*. 2004;30:723–728.
70. Breu FX, Guggenbichler S. European Consensus Meeting on Foam Sclerotherapy, April 4–6, 2003, Tegernsee, Germany. *Dermatol Surg*. 2004;30:709–717.
71. Scultetus AH, Villavicencio JL, Kao TC, Gillespie DL, Ketron GD, Iafrati MD, Pikoulis E, Eifert S. Microthrombectomy reduces postsclerotherapy pigmentation: multicenter randomized trial. *J Vasc Surg*. 2003;38:896–903.
72. Merchant RF, DePalma RG, Kabnick LS. Endovascular obliteration of saphenous reflux: a multicenter study. *J Vasc Surg*. 2002;35:1190–1196.
73. Hingorani AP, Ascher E, Markevich N, Schutzer RW, Kallakuri S, Hou A, Nahata S, Yorkovich W, Jacob T. Deep venous thrombosis after radiofrequency ablation of greater saphenous vein: a word of caution. *J Vasc Surg*. 2004;40:500–504.
74. Min RJ, Khilnani N, Zimmet SE. Endovenous laser treatment of saphenous vein reflux: long-term results. *J Vasc Interv Radiol*. 2003;14:991–996.
75. Danza R, Navarro T, Baldizan J. Reconstructive surgery in chronic venous obstruction of the lower limbs. *J Cardiovasc Surg*. 1991;32:98–103.
76. Neglen P, Raju S. Intravascular ultrasound scan evaluation of the obstructed vein. *J Vasc Surg*. 2002;35:694–700.
77. Neglen P, Raju S. In-stent recurrent stenosis in stents placed in the lower extremity venous outflow tract. *J Vasc Surg*. 2004;39:181–188.
78. Sarin S, Scurr JH, Coleridge Smith PD. Stripping of the long saphenous vein in the treatment of primary varicose veins. *Br J Surg*. 1994;81:1455–1458.

79. Aremu MA, Mahendran B, Butcher W, Khan Z, Colgan MP, Moore DJ, Madhavan P, Shanik DG. Prospective randomised controlled trial: conventional versus powered phlebectomy. *J Vasc Surg.* 2004;39:88–94.
80. Padberg FT Jr, Pappas PJ, Araki CT, Back TL, Hobson RW. Hemodynamic and clinical improvement after superficial vein ablation in primary combined insufficiency with ulceration. *J Vasc Surg.* 1996;24:711–718.
81. MacKenzie RK, Allan PL, Ruckley CV, Bradbury AW. The effect of long saphenous vein stripping on deep venous reflux. *Eur J Vasc Endovasc Surg.* 2004;28:104–107.
82. Barwell JR, Davies CE, Deacon J, Harvey K, Minor J, Sassano A, Taylor M, Usher J, Wakely C, Earnshaw JJ, Heather BP, Mitchell DC, Whyman MR, Poskitt KR. Comparison of surgery and compression with compression alone in chronic venous ulceration (ESCHAR study): randomized controlled trial. *Lancet.* 2004;363:1854–1859.
83. Gloviczki P, Bergan JJ, Rhodes JM, Canton LG, Harmsen S, Ilstrup DM. Mid-term results of endoscopic perforator vein interruption for chronic venous insufficiency: lessons learned from the North American subfascial endoscopic perforator surgery registry. The North American Study Group. *J Vasc Surg.* 1999;29:489–502.
84. Bianchi C, Ballard JL, Abou-Zamzam AM, Teruya TH. Subfascial endoscopic perforator vein surgery combined with saphenous vein ablation: results and critical analysis. *J Vasc Surg.* 2003;38:67–71.
85. Tawes RL, Barron ML, Coello AA, Joyce DH, Kolvenbach R. Optimal therapy for advanced chronic venous insufficiency. *J Vasc Surg.* 2003;37:545–551.
86. Kistner RL. Surgical repair of the incompetent femoral vein valve. *Arch Surg.* 1975;110:1336–1342.
87. Raju S, Berry MA, Neglen P. Transcommissural valvuloplasty: technique and results. *J Vasc Surg.* 2000;32:969–976.
88. Neglen P, Raju S. Venous reflux repair with cryopreserved vein valves. *J Vasc Surg.* 2003;38:1139–1140.